

The Effect of Intra-Articular Magnesium on the Articular Cartilage and Synovium in the Rat Knee Joint

¹Ansam Aly, M.D., ²Sherif Farouk, M.D. and ³Rasha M. Abdelatti, M.D.

¹Department of Physiology, Faculty of Medicine, Ain Shams University, Cairo, Egypt.

²Department of Anesthesiology, Faculty of Medicine, Ain Shams University, Cairo, Egypt.

³Department of Pathology, Faculty of Medicine, Ain Shams University, Cairo, Egypt.

Abstract: Objective: Magnesium sulfate has been shown to provide analgesia when administered into the knee joints. The aim of this study was to evaluate the histopathological effects of intraarticular administration of magnesium sulfate in the rat knee joint. Design: A total of 50 rats were given 0.25ml of magnesium sulfate (10%) by injection into the right knee joint and 0.25ml of 0.9% saline solution by injection into the left knee joint as control. Groups of ten rats were killed by a lethal injection of ketamine on 1st, 2nd, 7th, 14th and 21st days after drug administration. All the joints were prepared and sectioned for histopathological examination. Inflammatory changes in the joints were graded according to a five point scale. Results: There was no significant difference in inflammation and cartilage degeneration between control and magnesium groups. Conclusion: We can speculate that magnesium sulfate can be used safely through intraarticular route without any adverse effects.

Key words: magnesium sulphate; analgesia; postoperative; intraarticular; rat.

INTRODUCTION

Intraarticular (IA) local anesthetics are often used for the management and prevention of pain after arthroscopic knee surgery. Recent in vitro studies have demonstrated chondrotoxic effects of local anesthetics, with the greatest emphasis in bupivacaine toxicity (Chu, C.R., 2010).

Magnesium blocks N-methyl-D-aspartate (NMDA) receptors. NMDA receptor antagonists have been shown to effectively alleviate pain related behavior in animal model as well as in clinical situations (Fisher, K., 2000; Hewitt, D.J., 2000). NMDA receptors have been identified in the knee joints (Lawand, N.B., 1997). Magnesium sulfate has been shown to provide postoperative analgesia when administered into the knee joint after arthroscopy (Bondok, R.S., A.M. Abd El-Hady, 2006).

Intraarticularly administered drugs have different histopathological effects on articular cartilage and synovium (Irwin, M.G., 1998). In this study, we evaluated the effects of IA injection of magnesium sulfate on articular cartilage and synovium membrane of rat knee joints.

MATERIALS AND METHODS

All animal procedures and care were carried out according to the general guidelines of Faculty of Medicine, Ain Shams University Research Ethical Committee (FMASU REC) which conformed to the guiding principles of the International Council on Harmonization (ICH) and the Islamic Organization for Medical Sciences (IOMS), the United States Office for Human Research Protections and the United States Code of Federal Regulations and operates under Federal Wide Assurance No. FWA00006444. A total of 50 adult Sprague – Dawley rats weighing 250 – 300 g were anesthetized with 6-8 mg.kg⁻¹ intramuscular ketamine. Under aseptic conditions, 0.25ml of magnesium sulfate (100mg. ml⁻¹) was injected into the right knee joint and 0.25ml of physiological 0.9% saline into the left knee joint as control at the same time. The animals were then returned to their cages. Groups of ten rats were killed by a lethal injection of ketamine (30 mg. kg⁻¹) at 1st, 2nd, 7th, 14th and 21st days after drug administration. The knee joints were detached and examined for gross signs of hematoma. The joints were labeled (left / right and time of death), then placed in 10 percent buffered formalin for 2 weeks at room temperature. The joints were then decalcified in "De Castro" Solution consisting of 300 ml absolute alcohol, 670ml distilled water, 30 ml 70 percent nitric acid and 50 g chloral hydrate. Decalcification procedure lasted for four weeks at room temperature.

Decalcified tissue specimens were embedded in paraffin and processed for sectioning. Sectioning was carried out at 5µm intervals and the resulting slide preparations stained with haematoxylin and eosin. The same pathologist examined all the slides and was blinded to the treatment used in each joint.

Inflammatory changes in the joints were graded according to a five point scale. Grade 1- no inflammation, Grade 2- minimal inflammation: mild congestion and edema, Grade 3- mild inflammation: erosion of joint surface, congestion and edema, small number of neutrophils, Grade 4- moderate inflammation: neutrophils and

Corresponding Author: Ansam Aly, Department of Physiology, Faculty of Medicine, Ain Shams University, Cairo, Egypt.
Phone: 002-01099695572 Fax: 0020226365999
E-mail: ansamseif@yahoo.com

macrophages, synoviocyte hyperplasia, and Grade 5- severe inflammation: neutrophils and macrophages, synoviocyte hyperplasia, fibrin exudation.

Statistical Analysis:

The Mann – Whitney U test was used to compare differences between the experimental and control groups at 1st, 2nd, 7th, 14th and 21st days. P < 0.05 was considered to be a significant difference.

Results:

The incidence of hematoma over the joint capsule on gross examination was (magnesium: control) 1:1 at 1st day, 0:1 at 2nd day, 1:1 at 7th day and 0:0 at 14th and 21st days. All hematomas were small and the difference was not statistically significant.

The degree of histological inflammatory changes in each group is shown in table (1). There was no significant difference in inflammation and cartilage degeneration between control and magnesium groups at any time intervals (fig. 1- 4).

Table 1: Histopathological inflammatory changes in control and magnesium treated rat knee Joints.

| Magnesium group. | | | | | Control group | | | | | Grade (1-5) |
|------------------|---|---|---|----|---------------|---|---|---|----|-------------|
| 5 | 4 | 3 | 2 | 1 | 5 | 4 | 3 | 2 | 1 | |
| 0 | 0 | 0 | 5 | 5 | 0 | 0 | 0 | 2 | 8 | 1 |
| 0 | 0 | 0 | 3 | 7 | 0 | 0 | 0 | 2 | 8 | 2 |
| 0 | 0 | 0 | 2 | 8 | 0 | 0 | 0 | 1 | 9 | 7 |
| 0 | 0 | 0 | 2 | 8 | 0 | 0 | 0 | 0 | 10 | 14 |
| 0 | 0 | 0 | 0 | 10 | 0 | 0 | 0 | 0 | 10 | 21 |

Values are shown as number of rats according to the grade. No significant differences were found between the two groups.

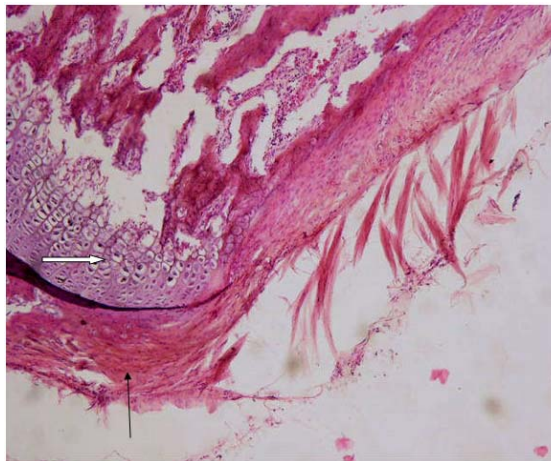


Fig. 1: Knee joint 1 day of rat after saline injection (control). There is regular intact articular cartilage. Synovium shows mild edema and congestion. Haematoxilin and eosin, ×100.

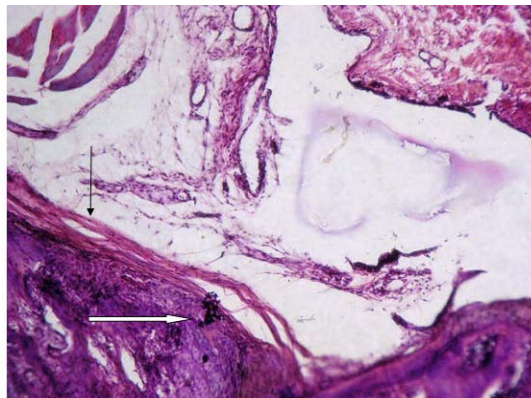


Fig. 2: Knee joint of rat 1 day after magnesium injection. There is regular intact articular cartilage. Synovium shows mild edema and congestion. Haematoxilin and eosin, ×100.

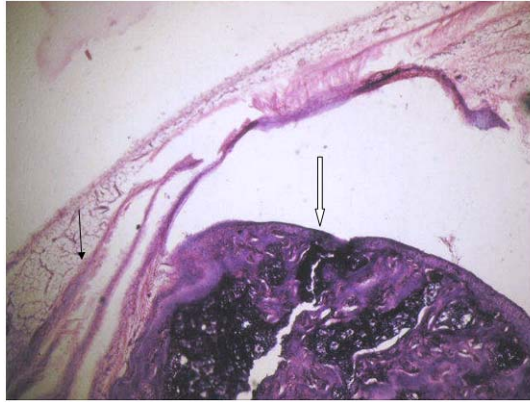


Fig. 3: Knee joint of rat 2 days after magnesium injection. There is regular intact articular cartilage. Synovium shows mild edema, no hyperplasia. Haematoxylin and eosin, $\times 100$.

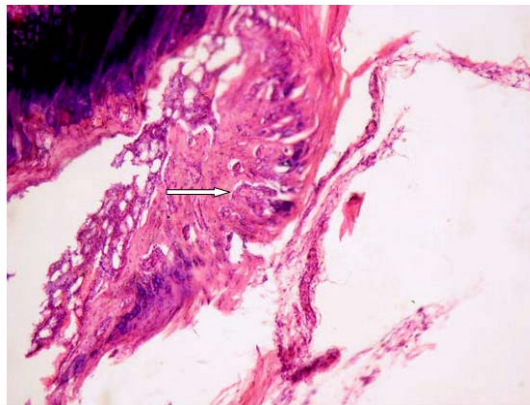


Fig. 4: Knee joint of rat 14 days after magnesium injection. There is regular intact articular cartilage. Haematoxylin and eosin, $\times 100$.

Discussion:

Magnesium is a bivalent ion, like calcium, the fourth most common cation in the body, and the second most common intracellular cation after potassium (Soave, P.M., 2009). Magnesium blocks NMDA channels in a voltage – dependent way, and the addition of magnesium produces a dramatic reduction of NMDA-induced currents (Ascher, P., L. Nowak, 1987). The NMDA receptor antagonism inhibits induction and maintenance of central sensitization after nociceptive stimuli (Fawcett, W.J., 1999). Magnesium is also a physiological calcium antagonist at different voltage-gated channels (Iseril, L.T., J.H. French, 1984) which may be important in the mechanisms of antinociception (Mantyh, P.W., 1994). Indeed, the local anesthetic properties of magnesium sulfate were first demonstrated more than a century ago (Meltzer, S.J., J. Auer, 1906).

Studies have identified NMDA receptors peripherally in the skin (Iwatsu, O., 2002), muscles (Caims, B.E., 2003) and knee joints and found that they play a role in the sensory transmission of noxious signals. Results suggest that IA administration of NMDA receptor antagonists has prophylactic analgesic effects in arthritic pain. Bondok and Abd El-Hady (2006) found that IA administration of magnesium sulfate at the end of arthroscopic knee surgery improved postoperative pain scores, increased the time to first rescue analgesic request and decreased the need for other analgesic medications. El Sharnouby *et al.* (El-Sharnouby, N.M., 2008) demonstrated that magnesium sulfate combined with bupivacaine produced a reduction in postoperative pain when given intraarticularly, in comparison to either bupivacaine or magnesium alone, or to saline placebo. IA administration of magnesium sulfate or morphine with bupivacaine had comparable analgesic effects and their combination provided more effective postoperative analgesia than either drug alone (Farouk, S., A. Aly, 2009). Another study by Chen and colleagues (Chen, Y., 2009) revealed that an intraoperative intraarticular magnesium sulfate and ropivacaine injection reduced the use of postoperative morphine following total knee arthroplasty.

Effective pain relief is an important parameter in discharge and rehabilitation in day case arthroscopic knee surgery. The histopathological effects of any drug administered locally are very important. The principle finding of the present study was that there were no significant histopathological differences between magnesium and

control groups. Baker and colleagues (Baker, J.F., 2011) assessed the human chondrocyte viability after treatment with local anesthetic, magnesium sulfate or normal saline and demonstrated that local anesthetic agents had a greater deleterious effect on chondrocytes than did 10% magnesium sulfate and there was no significant difference in chondrocyte viability after treatment with either normal saline or magnesium sulfate. Lee and colleagues (Lee, C.H., 2009) reported that local IA administration of magnesium sulfate following collagenase injection in an experimental rat osteoarthritis model attenuated the development of osteoarthritis and concomitantly reduced nociception.

In conclusion, we can speculate that magnesium sulfate can be used safely through intraarticular route without any adverse effects.

Contributions:

Ansam Aly:

- (1) the conception and design of the study, analysis and interpretation of data
- (2) revising the article critically for important intellectual content
- (3) final approval of the version to be submitted

This author takes responsibility for the integrity of the work as a whole, from inception to finished article.

Sherif Farouk:

- (1) the conception and design of the study, acquisition of data
- (2) critical revision of the article for important intellectual content, statistical expertise
- (3) final approval of the version to be submitted

Rasha Abdelatti:

- (1) the conception and design of the study, acquisition of data
- (2) drafting the article
- (3) final approval of the version to be submitted

Declaration of Funding:

- (1) No funding source; personal contribution from the authors themselves
- (2) Conflict of interest
- (3) No conflict of interest

REFERENCES

- Ascher, P., L. Nowak, 1987. Electrophysiological studies of NMDA receptors. *Trends Neurosci*, 10: 284-8.
- Baker, J.F., P.M. Walsh, D.P. Byrne, K.J. Mulhall, 2011. In vitro assessment of human chondrocyte viability after treatment with local anaesthetic, magnesium sulfate or normal saline. *Knee Surg Sports Traumatol Arthrosc.*, 19(6): 1043-6.
- Bondok, R.S., A.M. Abd El-Hady, 2006. Intra-articular magnesium is effective for postoperative analgesia in arthroscopic knee surgery. *Br J Anaesth.*, 97: 389-92.
- Bondok, R.S., A.M. Abd El-Hady, 2006. Intra-articular magnesium is effective for postoperative analgesia in arthroscopic Knee surgery. *Br. J Anaesth.*, 97: 389-92.
- Caims, B.E., P. Severson, K. Wang, S. Hupfeld, T. Graven-Nielsen, B.J. Sessle, C.B. Berde, L. Arendt-Nielsen, 2003. Activation of peripheral NMDA receptors contributes to human pain and rat afferent discharges evoked by injection of glutamate into the masseter muscle. *J. Neurophysiol.*, 90: 2098-105.
- Chen, Y., Y. Zhang, Y.L. Zhu, P.L. Fu, 2009. Efficacy and safety of intra-operative intra-articular magnesium / ropivacaine injection for pain control following total knee arthroplasty. *J Int Med Res.*, 37(6): 1733-41.
- Chu, C.R., C.H. Coyle, C.T. Chu, M. Szczodry, V. Seshadri, J.C. Karpie, K.M. Cieslak, E.K. Pringle, 2010. In vivo effects of single intra-articular injection of 0.5% bupivacaine on articular cartilage. *J Bone Joint Surg Am*, 92(3): 599-608.
- El-Sharnouby, N.M., H.M. Eid, N.F. Abou Elezz, A.N. Moharram, 2008. Intra-articular injection of magnesium sulfate and/or bupivacaine for postoperative analgesia after arthroscopic Knee surgery. *Anesth Analg*, 106: 1548-52.
- Farouk, S., A. Aly, 2009. A comparison of intra-articular magnesium and / or morphine with bupivacaine for postoperative analgesia after arthroscopic knee surgery. *J Anesth.*, 23(4): 508-12.
- Fawcett, W.J., E.J. Haxby, D.A. Male, 1999. Magnesium: physiology and pharmacology. *Br. J Anaesth*, 83: 302-20.
- Fisher, K., T.J. Coderre, N.A. Hagen, 2000. Targeting N-methyl- D- aspartate receptor for chronic pain management: Pre-clinical animal studies, recent clinical experience and future research directions. *J Pain Symptom Manage*, 20: 358-74.

- Hewitt, D.J., 2000. The use of NMDA – receptor antagonists in the treatment of chronic pain. *Clin J Pain*, 16: 573-9.
- Irwin, M.G., K.M.C. Cheung, J.M. Nicholls, N. Thompson, 1998. Intra-articular injection of Ketorolac in the rat knee Joint: effect on articular cartilage and synovium. *Br. J. Anaesth.*, 80: 837-839.
- Iseril, L.T., J.H. French, 1984. Magnesium: nature's physiologic calcium blocker (editorial) *Am Heart J.*, 108: 188-94.
- Iwatsu, O., T. Ushida, T. Tani, N.B. Lawand, H. Yamaoto, 2002. Peripheral administration of magnesium sulfate and ketamine hydrochloride produces hypoesthesia to mechanical stimuli in humans. *J Health Sci.*, 48: 69-72.
- Lawand, N.B., W.D. Willis, K.N. Westlund, 1997. Excitatory amino acid receptor involvement in peripheral nociceptive transmission in rats. *Eur J Pharmacol.*, 324: 169-77.
- Lee, C.H., Z.H. Wen, Y.C. Chang, S.Y. Huang, C.C. Tang, W.F. Chen, S.P. Hsieh, C.S. Hsieh, Y.H. Jean, 2009. Intra-articular magnesium Sulfate (MgSO₄) reduces experimental osteoarthritis and nociception; association with attenuation of N-methyl-D-Aspartate (NMDA) receptor subunit 1 phosphorylation and apoptosis in rat chondrocytes. *Osteoarthritis Cartilage*, 17(11): 1485-93.
- Mantyh, P.W., C.J. Allen, S. Rogers, E. De Master, J.R. Chilardi, T. Mosconi, L. Kruger, P.J. Mannon, I.L. Taylor, S.R. Vigna, 1994. Some Sensory neurons express neuropeptide Y receptors: potential paracrine inhibition of primary afferent nociceptors following peripheral nerve injury. *J Neurosci.*, 14: 3958-68.
- Meltzer, S.J., J. Auer, 1906. Physiological and pharmacological studies on magnesium salts. Narcotizing effect of magnesium salts upon nerve fibres. *Am J physiol.*, 16: 233-251.
- Soave, P.M., G. Conti, R. Costa, A. Arcangeli, 2009. Magnesium and anaesthesia. *Curr Drug Targets*, 10(8): 734-43.