

Montelukast as a New Topical Ocular Therapeutic Agent for Treatment of Allergic Conjunctivitis: an Experimental Comparative Study

¹Ghada Ghanem El-Hossary, ²Karim Abd El-Hamid Rizk, ¹Amany Hassan M. El-Shazly,
³Laila K. Hanafy

¹Pharmacology, ²Ophthalmology and ³Histology Departments, Research Institute of
Ophthalmology, Giza, Egypt

Abstract: The aim of the present investigation is to study the effects of topical ocular montelukast in an animal model of allergic conjunctivitis in rabbits. Eighteen Albino New Zealand rabbits were used and divided into six groups; three of which served as controls. Allergic conjunctivitis model was induced in the other three groups (IV, V and VI) by topical application of 1000 µg of compound 48/80 in each eye. Group IV was left untreated while groups V and VI were treated with 0.1% montelukast and 1% prednisolone eye drops respectively. The eye drops were applied before application of the compound. The eyes were evaluated by clinical examination and scoring of the allergic manifestations as well as by light microscopic examination of the conjunctiva. Both montelukast and prednisolone produced improvement of the allergic manifestations detected both clinically and histologically with prednisolone being more effective than montelukast. In conclusion, topical ocular montelukast can be a potential therapeutic drug with a new route of administration that can be used for treatment of allergic conjunctivitis.

Key words: montelukast, leukotrienes, experimental allergic conjunctivitis, clinical scoring, histopathological examination.

INTRODUCTION

Allergic conjunctivitis is a collection of hypersensitivity disorders that affect the lid, conjunctiva and cornea. It is characterized by immunoglobulin E (IgE)-mediated and/or T-lymphocyte-mediated immune hypersensitivity reactions (Chigbu de, 2009). These reactions are initiated by binding of an allergen with specific IgE on the surface of mast cells. The resultant mast cell degranulation leads to early phase and late phase responses. The early phase response develops immediately after exposure to the allergen with clinical symptoms and signs such as itching, chemosis and congestion. This is followed by the late phase response after 8-24 hours which is characterized by conjunctival cellular infiltrations particularly eosinophilia and neutrophilia (Miyazaki *et al.*, 2008). The pathophysiology of allergic conjunctivitis is not a simple process. New findings suggest that a wide range of cytokines, chemokines, proteases and growth factors are involved by complex interrelated interactions (Leonardi *et al.*, 2008). In allergic conjunctivitis, there is increased tear levels of several chemical mediators such as histamine, tryptase, leukotrienes (LTs) and prostaglandins (Ono and Abelson, 2005). In addition, tear levels of LTB4 and LTC4 were found to be significantly higher in patients with vernal keratoconjunctivitis than in controls (Akman *et al.*, 1998). In fact, leukotrienes play a role in the development of seasonal allergic conjunctivitis as well as the more severe forms as vernal keratoconjunctivitis and atopic keratoconjunctivitis (Leonardi *et al.*, 2008).

Treatment of allergic conjunctivitis includes several drug groups such as antihistamines, mast cell stabilizers, non-steroidal anti-inflammatory drugs and corticosteroids in resistant cases (Bielory and Friedlaender, 2008). However, the increased worldwide prevalence of ocular allergy has stimulated expansion of management strategies towards physiologic and immunologic drug targets. One of these targets is the leukotrienes (Schultz, 2006). Leukotrienes comprise a family of products of the 5-lipoxygenase pathway of arachidonic acid metabolism. The proinflammatory effects of leukotrienes have been well described in asthma and rhinitis (Sacre Hazouri, 2008). Leukotriene receptor antagonists have emerged as important therapeutic options that show clinical efficacy in treatment of bronchial asthma. Three specific leukotriene receptor antagonists are used

Corresponding Author: Ghada Ghanem El-Hossary, Pharmacology Department, Research Institute of Ophthalmology, Giza, Egypt.
E-mail gghossary@yahoo.com

clinically; namely montelukast, zafirlukast and pranlukast (Del Giudice *et al.*, 2009).

As regards the ocular effects, leukotriene receptor antagonists were reported to ameliorate ocular manifestations of some diseases. Oral montelukast was reported to decrease orbital congestion and inflammation in thyroid eye disease (Lauer *et al.*, 2008). In addition, oral montelukast treatment significantly decreased signs and symptoms of vernal keratoconjunctivitis associated with asthma (Lambiase *et al.*, 2003). Therefore, the present study is designed to investigate the effect of topical montelukast, prepared as 0.1% eye drops, in an animal model of allergic conjunctivitis.

MATERIALS AND METHODS

Animal Model:

The animal model of allergic conjunctivitis was induced by topical application of compound 48/80 (Sigma, Germany) in the rabbit eye. The compound, which is a mast cell degranulating agent, was applied once in a dose of 1000 µg. The dose was dissolved in 0.1 ml phosphate-buffered saline and the pH was adjusted to 7.4 with 0.1M NaOH. The control groups received 0.1 ml phosphate-buffered saline (Allansmith *et al.*, 1989).

Montelukast Eye Drops:

Montelukast was obtained as a drug powder from European Egyptian Pharmaceuticals, Egypt. Pilot experiments were performed so as to determine the proper concentration of montelukast that can be applied safely to the rabbit eyes as eye drops. Different concentrations of montelukast eye drops (1%, 0.5%, 0.25% and 0.1%) were prepared by dissolving the drug in 1% carboxymethylcellulose (ELN Co., Egypt). Each concentration was applied five times daily for three days to two rabbit eyes and the eyes were observed for any signs of irritation. The higher three concentrations produced some ocular irritation in the form of increased tearing and some dilated vessels. The lowest concentration didn't produce any signs of ocular irritation and was well tolerated when applied repeatedly to rabbit eyes. Therefore, in the present investigation, it was decided to use montelukast 0.1% eye drops dissolved in 1% carboxymethylcellulose.

Animal Groups:

Eighteen Albino New Zealand rabbits of both sexes weighing 1.5-2 Kgs were used. They were housed individually in separate cages under veterinary supervision. They were used in accordance with institutional guidelines and with the statement for use of animals in ophthalmic and vision research. They were fed with the standard diet and water and kept in 12 hours dark/light cycles under controlled temperature and humidity. Animals were divided into six groups each consisting of three rabbits (six eyes in each group).

a- Control Groups:

Group I. Rabbits received saline eye drops (negative controls).

Group II. The animals received 0.1% montelukast eye drops.

Group III. The animals received 1% prednisolone acetate eye drops (Pred Forte from Allergan, Ireland).

B- Allergic Conjunctivitis Model Groups:

Group IV. Rabbits received saline eye drops.

Group V. The animals received 0.1% montelukast eye drops.

Group VI. The animals received 1% prednisolone acetate eye drops.

In each group, the eye drops (saline, montelukast 0.1% or prednisolone acetate 1%) were applied seven times; six times the day before then one hour before application of compound 48/80 in the allergic conjunctivitis model groups or application of phosphate-buffered saline in the control groups.

Ophthalmological Examination:

Ophthalmological examination was performed using slit lamp biomicroscopy (Topcon). The clinical responses were graded using the grading criteria described by Miyazaki *et al.* (2008). For each eye, conjunctival edema, lid edema, tear/discharge and conjunctival redness were graded from 0-4. The cumulative clinical score was calculated as the sum of the scores of each of the four parameters with a range from 0-16. Examinations were performed 5 minutes, 15 minutes, 1 hour, 2 hours and 24 hours after application of compound 48/80 in the allergic conjunctivitis model groups or application of phosphate-buffered saline in the control groups. Before the experiment, all the rabbit eyes had a clinical score of zero.

Histopathological Examination:

Histopathological examination was carried out according to Drury and Wallington (1980). From each group, one animal was sacrificed after 2 hours and the remaining two rabbits after 24 hours. Conjunctival specimens were dissected and immediately double fixed in 4% glutaraldehyde buffer, then 1.3% osmium tetroxide in phosphate buffer (pH 7.3). The specimens were processed and embedded in araldite Cy 212. Semi-thin sections were stained with toluidine blue (TB) and examined by light microscopy.

Statistical Analysis:

Values of the clinical scoring were expressed as mean±SD. Analysis of variance (ANOVA) and student t test were performed to compare the values between groups. A post-hoc test was used to isolate significant differences if ($P < 0.05$).

RESULTS AND DISCUSSION**Ophthalmological Examination:**

All rabbit eyes in the three control groups had a clinical score of zero when examined at the previously mentioned time intervals so they are not included in the result table. In group IV, application of compound 48/80 to the ocular surface produced almost immediate manifestations in the form of lid edema, conjunctival edema, discharge and conjunctival redness. The latter three scoring criteria were evident and the scores ranged from 1-4 for each one. However, lid edema was not severe in these animals and was scored from 0-1 in all the eyes examined. The manifestations increased gradually and were most severe 1 hour after application of the compound with a clinical score of 10.67 ± 2.88 then decreased gradually to give a clinical score of 6.50 ± 0.58 at the end of the experiment (24 hours after compound application).

Treatment with topical montelukast (group V) exhibited clinical scores that were less than those seen with the untreated model at all time intervals of examination. Each criterion had a score from 1-4 except lid edema as all the eyes had a score of zero. The decrease in clinical scores was significant after 5 minutes, 15 minutes and 24 hours after compound application. However, this decrease was insignificant after 1 and 2 hours of application of the compound. In group VI, prednisolone topical treatment caused more marked decrease in the clinical scores. All the scoring criteria had scores that ranged from 1-3 except lid edema as all the eyes had a score of zero. The clinical scores were significantly lower than those of the untreated animals at all examinations performed on different time intervals. When the clinical scores of montelukast were compared to those of prednisolone, there was insignificant difference at all intervals except after 24 hours of compound application as the scores were significantly different with prednisolone being more effective.

Table 1: Means of clinical scores (\pm SD) recorded 5 minutes, 15 minutes, 1 hour, 2 hours and 24 hours after application of 1000 μ g of compound 48/80 in group IV (untreated allergic conjunctivitis model), group V (allergic conjunctivitis model pretreated with 0.1% montelukast eye drops) and group VI (allergic conjunctivitis model pretreated with 1% prednisolone eye drops).

Groups	Group IV	Group V	Group VI
Mean \pm SD after 5 minutes (n=6)	8.17 \pm 1.47	3.17 \pm 0.75	4.17 \pm 0.98
P1		0.000*	0.000*
P2			0.140
Mean \pm SD after 15 minutes (n=6)	10.17 \pm 2.48	4.17 \pm 0.41	4.00 \pm 0.89
P1		0.000*	0.000*
P2			0.854
Mean \pm SD after 1 hour (n=6)	10.67 \pm 2.88	7.00 \pm 3.79	4.67 \pm 2.94
P1		0.068	0.006*
P2			0.230
Mean \pm SD after 2 hours (n=6)	9.50 \pm 3.56	6.50 \pm 4.18	3.33 \pm 2.07
P1		0.146	0.007*
P2			0.126
Mean \pm SD after 24 hours (n=4)	6.50 \pm 0.58	2.25 \pm 0.50	0.75 \pm 0.50
P1		0.000*	0.000*
P2			0.003*

Data are expressed as mean \pm SD; * Significant difference at $p < 0.05$; P1 compared to group IV; P2 compared to group V.

Histopathological Examination:

Conjunctival specimens obtained from the negative control group I showed normal appearance. The conjunctival epithelium was approximately five to six layers thick with the goblet cells scattered through the epithelium. The substantia propria (stroma) consisted of delicate fibrous connective tissue that contained blood capillaries and few scattered inflammatory cells (Fig. 1). Examination of conjunctival specimens from the

positive controls (groups II and III) also exhibited a fairly normal histological picture. In group IV (untreated allergic conjunctivitis model), the specimens obtained 2 hours after compound application showed that the covering conjunctival epithelium was markedly attenuated with increased staining affinity and marked loss of goblet cells. The stroma showed hypercellularity consisting of fibroblasts and inflammatory cells. The blood vessels appeared congested and dilated (Fig. 2). Examination of the conjunctiva obtained after 24 hours of compound application revealed proliferated deeply stained epithelial cells with complete loss of goblet cells. The stroma showed dissolution of collagen fibers with few fibroblasts and many inflammatory cells. In addition, the blood vessels appeared dilated (Fig. 3).

Pretreatment of allergic conjunctivitis model rabbits with 0.1% montelukast eye drops (group V) exhibited histopathological picture after 2 hours of compound application that was different from the picture obtained after 24 hours. The changes observed after 2 hours of compound application were indistinguishable from those obtained from untreated allergic conjunctivitis model at the same time interval. The covering epithelium was thin with few goblet cells. The stroma appeared edematous and showed some inflammatory infiltration with dilated and congested blood vessels (Fig. 4). On the other hand, after 24 hours, the covering epithelium appeared fairly normal. The stroma exhibited less edema with few inflammatory cells and some dilated blood vessels (Fig. 5). Pretreatment of allergic conjunctivitis model rabbits with 1% prednisolone eye drops (group VI) exhibited marked improvement of the histopathological picture both after 2 and 24 hours of compound application. After 2 hours, examination revealed intact epithelium with few stromal inflammatory cells. Only some of the specimens showed mild stromal edema (Fig. 6). Examination of specimens obtained after 24 hours revealed unremarkable histological changes (Fig. 7).

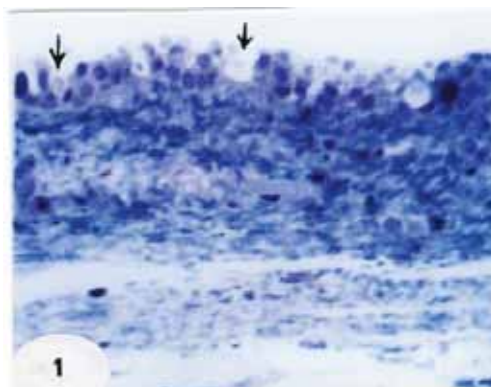


Fig. 1: Light micrograph of a semi-thin section of control rabbit conjunctiva (group I) showing the normal stratified squamous epithelium intermixed with goblet cells (arrows) resting on conjunctival substantia propria with few scattered inflammatory cells (TB X500).

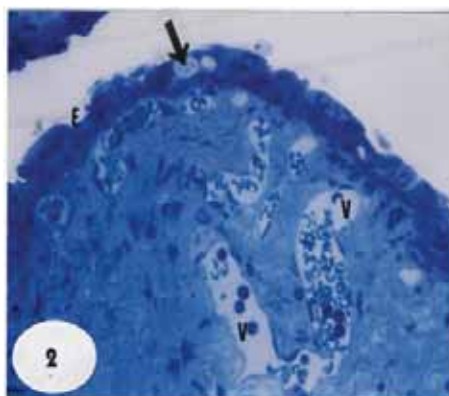


Fig. 2: Light micrograph of a semi-thin section of untreated allergic conjunctivitis model obtained 2 hours after compound application (group IV) showing stretched epithelium (E) and few goblet cells (arrow) with multiple congested and dilated blood vessels (V). The substantia propria shows inflammatory cellular infiltration (TB X500).

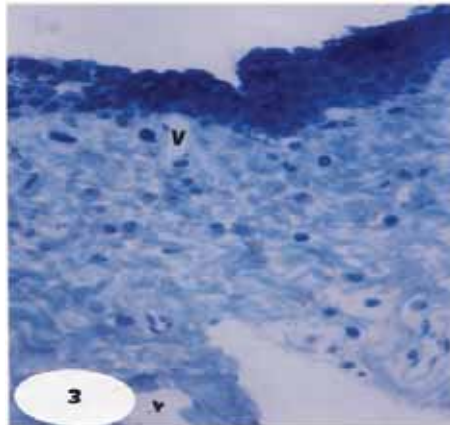


Fig. 3: Light micrograph of a semi-thin section of rabbit conjunctiva of group IV (untreated allergic conjunctivitis model obtained 24 hours after compound application) showing densely stained epithelium with scarcity of goblet cells. The stroma shows inflammatory cell infiltration and dilated blood vessels (V) (TB X500).

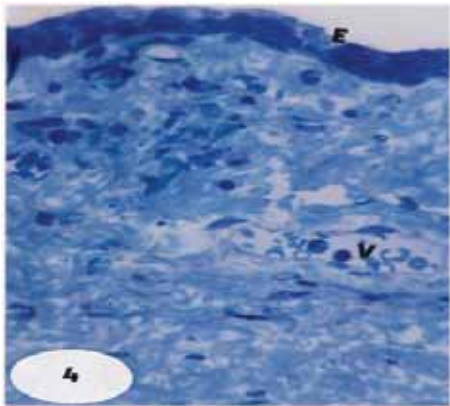


Fig. 4: Light micrograph of a semi-thin section of rabbit conjunctiva obtained 2 hours after compound application from group V (allergic conjunctivitis model pretreated with 0.1% montelukast eye drops) showing thinned epithelium (E) with few goblet cells. The stroma shows some inflammatory cellular infiltration with congested dilated blood vessels (V) (TB X500).




Fig. 5: Light micrograph of a semi-thin section of rabbit conjunctiva obtained 24 hours after compound application from group V (allergic conjunctivitis model pretreated with 0.1% montelukast eye drops) showing more or less normal epithelium (E) with few inflammatory cells (arrows) (TB X500).




Fig. 6: Light micrograph of a semi-thin section of rabbit conjunctiva obtained 2 hours after compound application from group VI (allergic conjunctivitis model pretreated with 1% prednisolone eye drops) showing normal appearance of epithelium and stroma with the exception of few inflammatory cells (arrows) and mild stromal edema (TB X500).

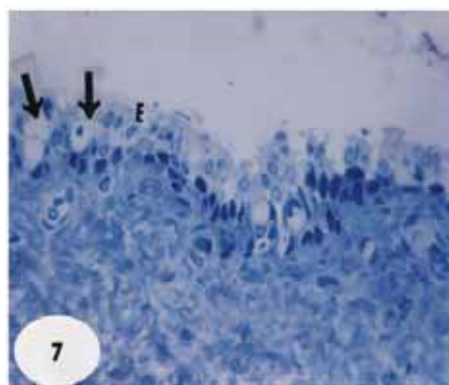


Fig. 7: Light micrograph of a semi-thin section of rabbit conjunctiva obtained 24 hours after compound application from group VI (allergic conjunctivitis model pretreated with 1% prednisolone eye drops) showing a fairly normal appearance of stroma and epithelium (E) with numerous goblet cells (arrows) (TB X500).

Discussion:

The ocular allergic response results from exposure of the conjunctiva to an environmental allergen and binding with specific IgE on the conjunctival mast cells. The resultant mast cell degranulation plays a key role in the pathogenesis of both the early and late phase responses of ocular allergy (Leonardi *et al.*, 2008). Compound 48/80 is a non-immunogenic mast cell degranulating agent that produces manifestations of external allergic inflammation when applied topically to the ocular surface (Allansmith *et al.*, 1989). The degranulation produced by the compound is less extensive but morphologically similar to that seen in vernal and giant papillary conjunctivitis. Therefore, it can serve as a useful tool for testing ocular anti-inflammatory agents (Udell *et al.*, 1989). In the present study, compound 48/80 applied topically to rabbit eyes produced allergic inflammatory manifestations that were evident on clinical examination of the eyes as well as on histopathological examination of conjunctival specimens. In accordance with our results, compound 48/80 was applied topically to rat eyes and exhibited clinical allergic manifestations as well as light microscopic changes that were almost similar to those observed in the present investigation (Allansmith *et al.*, 1989). In addition, the compound produced the same effects when applied topically to eyes of rabbits, guinea pigs and humans (Udell and Abelson, 1981). Moreover, Udell *et al.* (1989) reported that compound 48/80 (applied topically to human eyes) produced mast cell degranulation that was demonstrated by light and electron microscopic examination of conjunctival specimens.

Pretreatment of allergic conjunctivitis model rabbits with 0.1% montelukast eye drops (group V) exhibited improvement of ocular inflammatory manifestations both clinically and by histopathological examination. The

improvement was more evident after 24 hours of compound application. In agreement with the results of the present study, oral montelukast for 15 days produced significant and persistent reduction of ocular signs and symptoms in asthmatic patients with vernal keratoconjunctivitis (Lambiase *et al.*, 2003). In addition, Oral montelukast combined with oral cetirizine were effective in decreasing orbital congestion and inflammation in patients with thyroid eye disease (Lauer *et al.*, 2008). Moreover, oral zafirlukast, another leukotriene receptor antagonist similar to montelukast, could significantly attenuate the development of conjunctival edema and inhibit the increase in the number of eosinophils in rats with experimental allergic conjunctivitis (Minami *et al.*, 2004). Regarding topical ocular application of these drugs, topical application of a leukotriene receptor antagonist in combination with a cyclooxygenase inhibitor could significantly improve inflammatory manifestations in rabbit eyes burned with sodium hydroxide (Struck *et al.*, 1995) which is in line with the results of the present study. In addition, Papathanassiou *et al.* (2004) reported that topical application of zafirlukast to rat eyes, challenged with compound 48/80, produced significant inhibition of the late phase nitric oxide production of the conjunctival hypersensitivity response. The authors concluded that leukotriene receptor antagonists might contribute to the management of ocular inflammatory response (Papathanassiou *et al.*, 2004). Outside the eye, inhaled montelukast could significantly inhibit the bronchoconstriction induced by LTC₄ and LTD₄ with no injury to the lung tissue in an animal model of asthma (Muraki *et al.*, 2009) and this demonstrates the therapeutic effectiveness and safety of locally applied montelukast which agrees with our results.

Montelukast is a leukotriene receptor antagonist that is currently used to treat persistent asthma (Jarvis and Markham, 2000). In the present study, it is believed that montelukast produced its effects in treatment of allergic conjunctivitis partly through the same mechanism but other mechanisms may have been involved. Although leukotrienes play a role in development of allergic conjunctivitis, they are not the only mediators involved in this disease. Histamine, tryptase and prostaglandins are also involved in the immediate allergic response (Ono and Abelson, 2005). In addition, mast cell degranulation induces activation of vascular endothelial cells and thus the expression of several chemokines and adhesion molecules that finally lead to the ocular allergic late phase reaction (Leonardi *et al.*, 2008). Moreover, conjunctival and corneal epithelial cells and fibroblasts may contribute to mounting the allergic inflammation by expressing and producing cytokines, chemokines, adhesion molecules and growth factors that maintain local inflammation and lead to tissue remodeling (Leonardi *et al.*, 2006). Montelukast was reported to significantly attenuate LT-induced degranulation of bone marrow derived mast cells (Kaneko *et al.*, 2009). The drug was also found to inhibit the expression of vascular endothelial growth factor and its receptors in lung tissue of experimentally induced asthma in rats (Yang *et al.*, 2009). Vascular endothelial growth factor is overexpressed in vernal keratoconjunctivitis and may involve tissue growth and remodeling that occur in severe cases of this disease (Asano-Kato *et al.*, 2005). Montelukast may have produced its beneficial effects in the present study through one of the previously mentioned mechanisms or through affecting different other mediators involved in allergic conjunctivitis in addition to its leukotriene receptor antagonistic activity. However, these assumptions need to be further investigated.

In group VI, pretreatment of allergic conjunctivitis model rabbits with 1% prednisolone produced more improvement of the allergic response than montelukast detected by significant decrease in the clinical scores at all time intervals of examination and by marked improvement of the histopathological picture as the conjunctiva appeared fairly normal after 24 hours of compound application. Topical corticosteroids are very effective in the treatment of allergic conjunctivitis. They have a variety of actions that play a role in suppressing the allergic diseases and their role is well documented in both clinical and experimental situations (Reiss *et al.*, 1996). Therefore, it is expected and logical that topical prednisolone was more effective than topical montelukast in the present study.

In conclusion, topical ocular montelukast can be a potential therapeutic drug with a new route of administration that can be used for treatment of allergic conjunctivitis. As new therapeutic strategies are still needed to respond to the complex pathogenesis of severe forms of ocular allergy, we believe that montelukast can be an add-on therapy in resistant cases of ocular allergic diseases.

REFERENCES

- Akman, A., M. Irkeç and M. Orhan, 1998. Effects of Iodoxamide, disodium cromoglycate and fluorometholone on tear leukotriene levels in vernal keratoconjunctivitis. *Eye (Lond.)*, 12(Pt 2): 291-295.
- Allansmith, M.R., R.S. Baird, R.S. Ross, N.P. Barney and K.J. Bloch, 1989. Ocular anaphylaxis induced in the rat by topical application of compound 48/80. *Acta Ophthalmol.*, 67(S192): 145-153.

- Asano-Kato, N., K. Fukagawa and N. Okada, 2005. TGF-beta 1, IL-1beta, and Th2 cytokines stimulate vascular endothelial growth factor production from conjunctival fibroblasts. *Exp. Eye Res.*, 80: 555-560.
- Bielory, L. and M.H. Friedlaender, 2008. Allergic conjunctivitis. *Immunol. Allergy Clin. North Am.*, 28(1): 43-58.
- Chigbu de, G.I., 2009. The pathophysiology of ocular allergy: a review. *Cont. Lens Anterior Eye*, 32(1): 3-15.
- Del Giudice, M.M., A. Pezzulo, C. Capristo, E. Alterio, S. Caggiano, D. Benedictis and A. F. Capristo, 2009. Leukotriene modifiers in the treatment of asthma in children. *Ther. Adv. Respir. Dis.*, 3(5): 245-251.
- Drury, R.A. and E.A. Wallington, 1980. *Carleton's histological techniques*. Oxford Univ. Press, pp: 241-242.
- Jarvis, B. and A. Markham, 2000. Montelukast: a review of its therapeutic potential in persistent asthma. *Drugs*, 59(4): 891-928.
- Kaneko, I., K. Suzuki, K. Matsuo, H. Kumagai, Y. Owada, N. Noguchi, T. Hishinuma and M. Ono, 2009. Cysteinyl leukotrienes enhance the degranulation of bone marrow-derived mast cells through the autocrine mechanism. *Tohoku J. Exp. Med.*, 217(3): 185-191.
- Lambiase, A., S. Bonini, G. Rasi, M. Coassin and A. Bruscolini, 2003. Montelukast, a leukotriene receptor antagonist, in vernal keratoconjunctivitis associated with asthma. *Arch. Ophthalmol.*, 121(5): 615-620.
- Lauer, S.A., R.Z. Silkiss and S. A. McCormick, 2008. Oral montelukast and cetirizine for thyroid eye disease. *Ophthal. Plast. Reconstr. Surg.*, 24(4): 257-261.
- Leonardi, A., L. Motterle and M. Bortolotti, 2008. Allergy and the eye. *Clin. Exp. Immunol.*, 153(S1): 17-21.
- Leonardi, A., S. J. Curnow, H. Zhan and V. L. Calder, 2006. Multiple cytokines in human tear specimens in seasonal and chronic allergic eye disease and in conjunctival fibroblast cultures. *Clin. Exp. Allergy*, 36: 777-784.
- Minami, K., Y. Fujii and C. Kamei, 2004. Participation of chemical mediators in the development of experimental allergic conjunctivitis in rats. *Int. Immunopharmacol.*, 4(12): 1531-1535.
- Miyazaki, D., T. Tominaga, K. Yakura, C. Kuo, N. Komatsu, Y. Inoue and S.J. Ono, 2008. Conjunctival mast cell as a mediator of eosinophilic response in ocular allergy. *Mol. Vis.*, 14: 1525-1532.
- Muraki, M., S. Imbe, R. Sato, Y. Ikeda, S. Yamagata, T. Iwanaga and Y. Tohda, 2009. Inhaled montelukast inhibits cystinyl-leukotriene-induced bronchoconstriction in ovalbumin-sensitized guinea-pigs: the potential as a new asthma medication. *Int. Immunopharmacol.*, 9(11): 1337-1341.
- Ono, S.J. and M.B. Abelson, 2005. Allergic conjunctivitis: update on pathophysiology and prospects for future treatment. *J. Allergy Clin. Immunol.*, 115: 118-122.
- Papathanassiou, M., V. Giannoulaki and E. Tiligada, 2004. Leukotriene antagonists attenuate late phase nitric oxide production during the hypersensitivity response in the conjunctiva. *Inflamm. Res.*, 53(8): 373-376.
- Reiss, J., M.B. Abelson, M.A. George and H.J. Wedner, 1996. Allergic conjunctivitis. In *Ocular infection and immunity*, Eds., Pepose, J.S., G.N. Holland and K.R. Wilhelmus. Mosby-Year Book Inc., pp: 345-358.
- Sacre Hazouri, J.A., 2008. Leukotriene antagonists in the treatment of allergic rhinitis and comorbiditis. *Rev. Alerg. Mex.*, 55(4): 164-175.
- Schultz, B.L., 2006. Pharmacology of ocular allergy. *Curr. Opin. Allergy Clin. Immunol.*, 6(5): 383-389.
- Struck, H.G., S. Giessler and C. Giessler, 1995. Effect of non-steroidal anti-inflammatory drugs on inflammatory reaction. An animal experimental study. *Ophthalmologe*, 92(6): 849- 853.
- Udell, I.J. and M.B. Abelson, 1981. Animal and human ocular surface response to a topical non-immune mast cell degranulating agent (compound 48/80). *Am. J. Ophthalmol.*, 91, 226-230.
- Udell, I.J., K.R. Kenyon, L.A. Hanninen and M.B. Abelson, 1989. Time course of human conjunctival mast cell degranulation in response to compound 48/80. *Acta Ophthalmol.*, 67(S192): 154-161.
- Yang, H.S., L. Wang, W. Yang, J.T. Guan, J.Y. Ma and Y. Su, 2009. Effects of leukotriene receptor antagonists on vascular endothelial growth factor and its receptors in a sensitized rat model. *Zhonghua Jie. He. Hu. Xi. Za. Zhi.*, 32(3): 177-181.