Australian Journal of Basic and Applied Sciences, 4(1): 61-70, 2010
ISSN 1991-8178

Electrophoretic and Histopathological Studies on Adult Female Rats Treated with Depo-Provera (DMPA)

Sayed Bakry and Waleed Abu-Shaeir

Zoology Department, Faculty of Science, Al Azhar University, Cairo, Egypt

Abstract: Medroxyprogesterone Acetate (DMPA) is a long-acting, injectable progesterone derivative contraceptive and classified as sex hormone binding globulin (SHBG). In this study the effect of (DMPA) on serum protein patterns, hepatic and renal tissues were investigated on adult female rats. Sixty mature healthy female rats with average body weight ranged 130 – 200 g, 40 of them were injected IM with DMPA human therapeutic (150 and 300 mg) equivalent to rat doses (2.7 or 5.4 mg/ rat/ week) and sacrificed after four and six weeks of the treatment. Sera total proteins, liver functions and electrophoretic analyses were quantified as well as liver tissues were removed and fixed. The Student's "t"-distribution were adopted for assessment of significant changes occurring between the groups. DMPA was found to reduce the concentrations of both serum total protein and serum protein fractions (Prealbumin, Albumin and globulin "ά-β & γ") of the treated rats as well as several band discomfitures. DMPA induced histopathological lesions in liver and kidneys tissues of the treated rats which represented by; Lymphocytic infiltration as well as dilated and edematous blood vessels. The majority of liver cells their cytoplasm displayed signs of degeneration represented by cytoplasmic vacuolization and necrosis. The findings shed more light and traceable to effects of DMPA on the adult female rats and suggests a toxic potential of DMPA which makes this an important issue that is worthy of animal trials studying possible ill-effects. It demands the lowest possible use of effective doses of DMPA to minimize any potential risk.

Key words: DMPA, Serum Protein Electrophoresis, Liver, Histopathological lesions.

INTRODUCTION

Depot medroxyprogesterone acetate (DMPA) is a highly effective contraceptive method. It has been used as a contraceptive agent by millions of women in more than 90 countries since 1967 and was approved for use in several developing countries in 1992. The contraceptive mode was a depot injection containing 150mg medroxyprogesterone acetate which administered by intramuscular route at a plasma concentration of about 1ng/ml (Kahn *et al.,* 2003). Nearly 12 million women worldwide use injectable, progestin-only formulation over long intervals (United Nations Development Programme, 1997).The use of DMPA the contraception associated with significant increase in serum levels of albumin, alpha 1-acid glycoprotein, alpha 2-macroglobulin, haptoglobin, IgG; reduced levels of alpha 1-antitrypsin, transferrin, C3c, C4 but no change in serum IgA, IgM, C-reactive protein and ceruloplasmin in fifty women used DMPA (Fajumi, 1984). While, no significant changes were observed in Indian users of DMPA at the levels of IgA, IgM, total protein, and albumin. But, IgG levels were increased in the first and third month after DMPA injection, and the increase in the first month was statistically significant (Lali *et al.,* 1996). Significant increase in IgG levels was induced by long-acting, 19-nor-progesterone derivative, implantable contraceptive in healthy Nigerian women in the reproductive age during one year of use. (Adekunle *et al.,* 2001). Effect of DMPA, levonorgestrel, and gestodene induced marked decrease in the serum protein fractions specially SHBG (Wilhelm *et al.*, 2003). Human sex hormone-binding globulin (SHBG), produced in the liver, is the specific plasma transport protein for testosterone and estradiol that modulates the androgen to estrogen balance (Rosner, 1990 and Hammond, 1995). Low SHBG is associated with an increased androgenic environment, which has been shown to be associated with an adverse blood lipid profile. Many studies have shown that SHBG levels correlate positively with HDL-cholesterol concentrations (Haffner *et al.*, 1989; Pugeat *et al.* 1995 and Mingrone *et al.*, 2002). Progestins appeared to be directly related to the lower concentration of albumin in 4057 current users of progestin including DMPA were enrolled in

Corresponding Author: Sayed Bakry, Zoology Department, Faculty of Science, Al Azhar University, Cairo, Egypt.
E-mail: sayed.bakry@yahoo.com

a longitudinal study to determine the side effects of progestational contraceptive drugs on serum proteins, albumin and gamma globulin (Savitr *et al.,* 2006). DMPA associated with an initial significant increase in their mean values of concentration of C- reactive protein (CRP), total protein and body weights of the young women. The increase in the concentration of C- reactive protein (CRP) in the contraceptive users could affect the risk of venous thromboembolism, cardiovascular disease, and other oral contraceptive-associated adverse conditions (Westhoff *et al.,* 2007; Xiang *et al.,* 2007; Cauci *et al.*, 2008 and Meendering *et al.*, 2008). Also, DMPA 10 mg injection for 6 weeks induced reduction in the concentration of total serum IgG of female mice (Grant *et al.*, 2009).

Referring to histopathological lesions induced by progestin either oral or injectable contraceptives several publications reviewed; multiple nodular hyperplasia of liver was reported among the users of contraceptives manifested by marked vascularity and dilated hepatic sinusoids (Roschlau, 1977). Histological and electron microscopic studies of hepatocytes of biopsies from liver of young women who had used contraceptives revealed that liver is a target organ for estrogen and progesterone (Adlercreutz and Tenhunen, 1970 and Attia *et al.*, 1994). Excess of estrogen and/or progesterone produced hepatic morphological, biochemical and carcinogenic changes (Raufman *et al*., 1980 and Adieb *et al.*, 1986). Estrogen and progesterone (Ghonim, 1987 and Edress *et al.*, 1991) also cause congestion in the kidney, lymphocytic aggregation, local hemorrhage and cystic dilation of renal tubules. Liver tumors has been reported in women with age ranged between (20 – 30 years old) treated for several years with oral contraceptives. It was found that; there are several histopathological lesions discriminated from hemorrhage due to rupture of adenomas, multiple adenomas (liver adenomatosis), multiple liver lesions, hypoechogenic nodular image of 8 cm in the right hepatic lobe of the liver, focal nodular hyperplasia, severe hepatic reactions hepatic failure, and hepatocellular carcinoma (Rumi *et al.,* 2000; Nakao *et al.,* 2000; Tajada *et al.,* 2001; Giordano *et al.,* 2001 and Abe *et al.,* 2002). Moreover, histological examination of the liver of estrogen- and/or progesterone- treated animals revealed destruction of the liver architecture, cytoplasmic vaculation of the hepatocytes, fatty infiltrates and a remarkable abundance of phagocytic infiltrates. On the other hand; the kidney showed marked changes of congestion, perivascular and interstitial lymphocytic infiltrations, degeneration of some renal corpuscles and renal tubules. Such cells showed progressive degeneration of their nuclei and necrosis (Al-Rawi, 2002). Transaminases as ALT and AST are very imprtant marker for liver injury, ALT is a more specific indication of liver disease, whereas AST elevations may be secondary to damage of other organs. Also, the elevated levels of alkaline phosphatase may be caused by injury to the liver, bone, kidneys, intestines, placenta, or leukocytes (Giboney, 2005; Heidelbaugh and Bruderly, 2006; Navarro and Senior, 2006; Hoefs *et al.*, 2006 and Pritchett*,* 2009).

MATERIALS AND METHODS

The present study was carried using mature female albino rats (*Rattus norvigcus*) of an average body weight (160 - 200g). They were apparently normal, healthy animals. They were housed in animal houses under regular periods of dark and light i.e. (12-hrs dark and 12 -hrs light) at room temperature. Standard diet and water were provided ad.libitum. The animals were classified into six groups (10 rats each). Groups 1&4 was untreated and kept as control, groups 2&3 was injected with DMPA (2.7 or 5.4mg/rat/week) respectively for four weeks. While, groups 5&6 was injected with DMPA (2.7 or 5.4mg/rat/week) respectively for six weeks. All treated groups were injected intramuscularly (i. m.) with the hormones every 5 days for 3 months. The doses were converted from human dose (150mg & 300mg) to rat (2.7mg/rat and 5.4mg/rat) dose by using multiplication factors for dose conversion between different species by Paget and Barnes (1964). Four and six weeks post-injection the experiments were terminated by cervical dislocation. Heart blood samples were drawn and refrigerated for one hour to clot. Samples were then centrifuged for 5 minutes and the supernatant serum frozen at -20°C for ten days until protein and liver enzyme measurements carried out according to method of Zilva *et al.* (1988) as well as electrophoretic investigations according to methods of Hames and Rick-Wood (1981). Gels were photographed, interpretation was carried out using 1D-main software version Windows (AABI: Advanced American Biotech Imaging. 1D Main Software). Bands of the serum total proteins were defined according to the methods of Marshall (1984) and Przyjalkowski and Starzenska (1985). The statistical analysis of the obtained data was done according to Baily (1994) and the analysis was revised by SPSS 10 for windows (2003). For histological study, liver removed washed in saline (0.9% NaCl) fixed in neutral buffered formalin fluid for 24 hours. After fixation, the tissues were dehydrated through ascending grades of ethanol and cleared in xylene and finally embedded in paraffin wax. Paraffin sections of 5 µm thickness were prepared then deparaffinized and stained with Ehrlich's haematoxlin and counterstained with eosin according to methods of Davenport (1960) and Humason (1979).

RESULTS AND DISCUSSION

Biochemical Assay:

DMPA doses for four and six weeks to adult female rats induced decrease in the concentration (g/dl) of serum total proteins (maximum ~ -83.10 %) in the treated groups compared with the controls. Also, liver enzyme activities following hormonal treatment exhibited a significant reduction of alkaline phosphatase (Alp) activity (-18.46 %) as well as significant increase of asparate transaminase (AST) (+82.76 %) and alanine transaminase (ALT) (+91.28 %) were noticed in sera of treated groups (As shown in Table 1). These decreases were statistically highly significant ($P \leq 0.01$) decrease when compared with the control group.

Table 1: Effect of DMPA doses on the concentration of serum total proteins (mg/dl), alkaline phosphate (µ/l), and asparate- and alanine transaminases (µ/l).

Groups	After Four Weeks			After Six Weeks		
	Control	GII	GIII	Control	GV	GVI
T.P. mg/dl	6.18 + 1.9	4.58** + 1.6	3.66** + 1.3	6.24 + 1.4	3.97** + 1.10	2.97** + 2.10
%	--	- 25.88 %	- 55.03 %	--	- 61.48 %	- 83.10 %
Alp µ/l	129.16 ± 0.1	112.11 ± 0.1*	108.51 ± 1.1*	127.25 ± 1.1	110.31 ± 1.6*	103.75 ± 1.1**
%	--	- 13.20 %	- 15.98 %	--	- 13.31 %	- 18.46 %
AST µ/l	91.32 ± 1.4	148.51 ± 1.7**	164.14 ± 2.3**	92.74 ± 2.1	150.81 ± 2.6**	169.50 ± 1.3**
%	--	0.6262	0.7974	--	0.6261	0.8276
ALT µ/l	27.81 ± 0.6	43.28 ± 0.7**	51.26 ± 0.1**	29.60 ± 0.8	49.26 ± 0.5**	56.62 ± 0.4**
%	--	0.5562	0.8432	--	0.6641	91.28

Each value represents mean ± Standard deviation (N= 10) (*, **) Significant at P< 0.05 and P< 0.01, respectively. % = Percentage of change from the Control. T.P.= Total Protein, (ALP) = Alkaline Phosphate (AST) = Asparate Transaminase (ALT) = Alanine Transaminase

Electrophoretic Assay:

Data of scanned SDS-PAGE (SDS-poly acrylamide gel electrophoresis) of sera proteins of control and treated rats for both four and six with DMPA doses, indicated several alterations in the protein bands that are virtually always seen in normal serum. These bands are gamma, beta, alpha-globulin, albumin and prealbumin.

Concentration of Protein Bands:

DMPA induced discomfiture in serum protein bands represented by increase in bands number (maximum ~ 18.00 bands) as shown in plate (1). Also, induced decreases in the separated protein bands which was dose dependant. DMPA induced decreases in concentration of γ, β and α- globulin as well as prealbumin and albumin this decreases reached (maximum ~ -83.10%, -60.71%, -65.83%, -45.45 % and -80.37%) respectively. These changes were statistically highly ($P \leq 0.01$) in all groups when compared with the corresponding control group (As shown in Table 2).

Table 2: Effect of DMPA on the concentration of serum proteins (mg/dl) of the female rats.

Groups	After Four Weeks			After Six Weeks		
	Control	GII	GIII	Control	GV	GVI
No. Bands	14	15	16	13	17	18
γ- Globulin	1.49 + 0.03	1.37** + 0.06	0.67** + 0.01	1.48 + 0.05	0.57** + 0.01	0.25** + 0.01
	--	- 25.88 %	- 55.03 %	--	- 61.48 %	- 83.10 %
β- Globulin	0.83 + 0.04	0.66* + 0.01	0.66** + 0.01	0.84 + 0.03	0.68** + 0.02	0.33** + 0.01
	--	- 10.84 %	- 20.48 %	--	- 19.04 %	- 60.71 %
Albumin	1.36 + 0.06	0.57** + 0.05	0.74** + 0.05	1.56 + 0.09	0.66** + 0.03	0.54** + 0.01
	--	- 58.08 %	- 55.88 %	--	- 57.69 %	- 65.38 %
Prealbumin	0.55 + 0.03	0.43* + 0.04	0.31** + 0.01	0.66 + 0.03	0.41** + 0.01	0. 36** + 0.04
	--	- 21.81 %	- 43.63 %	--	- 37.87 %	- 45.45 %
α- Globulin	1.87 + 0.03	1.66* + 0.03	1.12** + 0.04	2.14 + 0.04	1.62** + 0.02	0.42** + 0.02
	--	- 11.22 %	- 40.10 %	--	- 24.29 %	- 80.37 %

Where: Data expressed as Mean + Standard Error , % = Percentage of change from the Control & ** = Highly Significant.

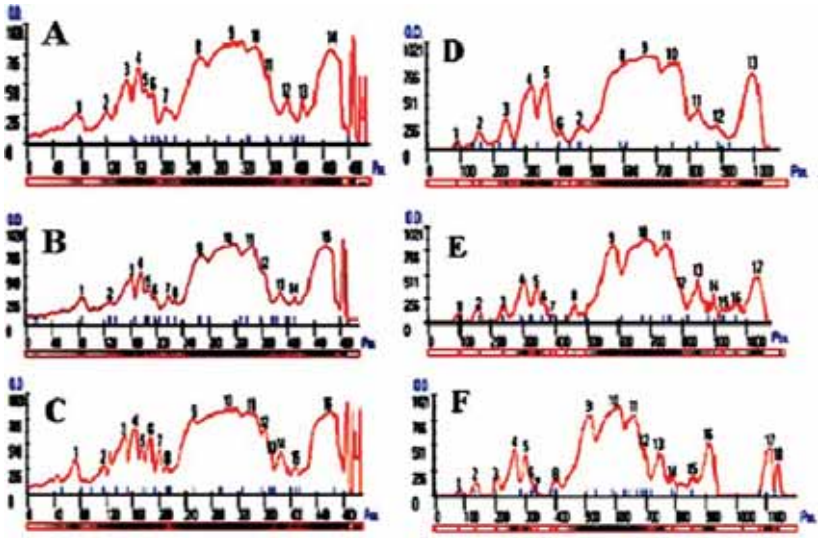

Plate 1: Electropherogram of Serum proteins from control and treated and female rats with DMPA after Four and Six weeks.
Where: A&D- Control, B, C, D and F, from GII, GIII, GV and GVI respectively.

Cluster Analysis:

Dendrogram was used to assess the relationship between the different band positions and the distance moved by these bands as shown in Figs. (1 & 2). Dendrograms constructed for serum protein bands after four weeks dependant on band matching and amount of proteins of this band revealed that the similarity index between control and both GII and GIII (14.03%) and dissimilarity reached (85.97%). While, similarity index between GII and GIII reached 54.67%) and dissimilarity 45.33% respectively as shown in Fig. (1).

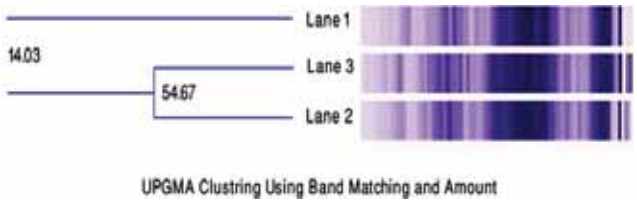

Fig. 1: Dendrogram of separated serum protein bands of treated and control female rats after four weeks. Where: Lane 1=Control, Lane 2=GII and Lane 3= GIII.

On the other hand, similarity index between control and treated groups GV and GVI belonging six weeks of treatment shown in Fig. (6). The data revealed that the similarity index between control and GV (47.09%) and dissimilarity index reached 52.91%. While, similarity index between GVI, GV and control reached 29.12% and dissimilarity 70.88% respectively as shown in Fig. (2).

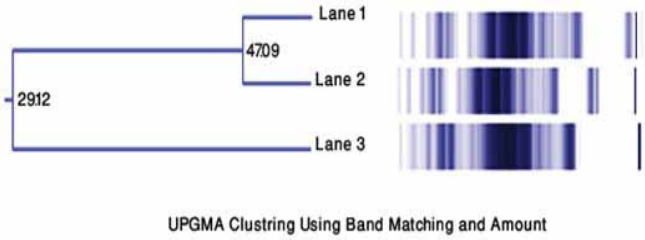

Fig. 2: Dendrogram of separated serum protein bands of treated and control female rats after six weeks. Where: Lane 1=Control, Lane 2=GV and Lane 3= GVI.

Histopathological Examination:

DMPA induced different histophathological lesions which were found to be dose dependent. The most remarkable effect of DMPA doses was the disturbance of the liver architecture and these effects were dose dependant. The liver sections of the control rats exhibited the classical histological appearance as shown in (Plate 2A). Meanwhile, liver sections of DMPA treated rats showed focal pathological changes. Some areas exhibited an increase in the acidophilic and granular appearance of binucleated hepatocytes, together with dilated, edematous and congested blood vessel (Plate 2B&D). Massive cytoplasmic vacuolization, nuclear pyknosis and bilirubin pigments with brown appearance throughout the liver tissues infiltration with proliferation of von-Kupffer cell are seen in (Plate 2B, D, and E, G & H). Also, irregular with detached endothelial lining blood vessels were observed in (Plate 2H). DMPA doses caused disorientation of hepatic strands of hepatic lobules. Hepatic cells enlarged with fatty infiltrates and cytoplasmic vacuols. Remarkable inflammatory cellular infiltration was noted (Plate 2G). Hepatocytes manifested clear necrotic signs as pyknosis and karyolysis of the nuclei (Plate 2E, F, and G&H).

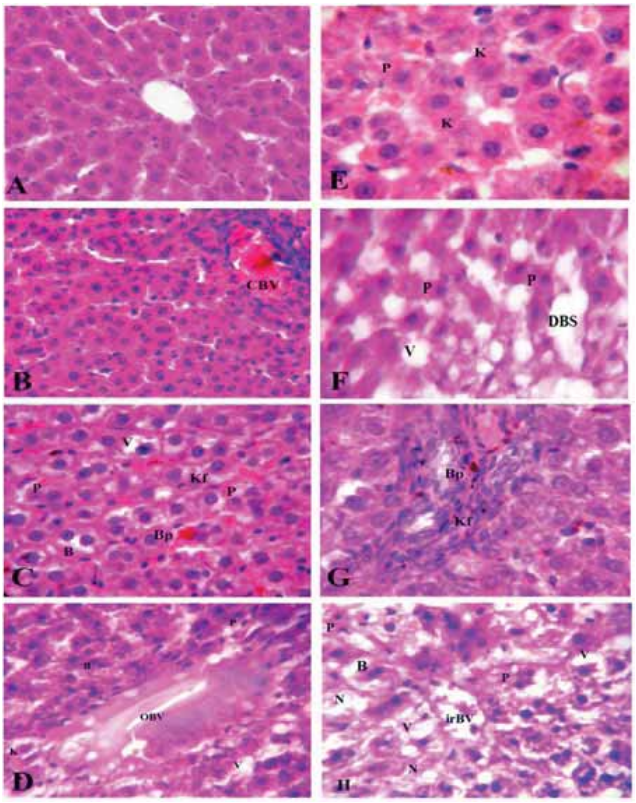

Plate 2: Histopathological Lesions induced by DMPA in liver tissues of treated female rats.

A, control liver section x20; B (X10), C (x40), D (x40), E (x100), F (x40), G (x100) & H (x40) are liver sections from treated female rats with DMPA doses. CBV, congested blood vessel; V, vacuole; Bp, bile pigments; P, pyknosis; Kf, Kupffer cells; OBV, oedemateous blood vessel; B, binucleated hepatocytes; N, necrotic area; DBS, dilated blood sinusoids; irBV, irregular blood vessel.

Discussion:

In the present study, the long-term use of DMPA results was found responsible for the reduction of serum total protein concentrations (gm/dl) and alkaline phosphatase (µ/l). Also, DMPA doses induced increase in the concentration (µ/l) of both asparate transaminase (AST) and alanine transaminase (ALT). Results of serum chemistry are used to determine their tissue dysfunction or damage in clinical and veterinary studies (Folmar *et al.*, 1993). The decreased serum total protein concentrations (gm/dl) levels are in agreement with Bakry (2005) and alkaline phosphatase levels in the present work was recorded by El-Allawy *et al.* (1984) and El-Gendy and Tohamy (1998) and in agreement with Voetberg *et al.* (1994) who attributed this decrease to the

inhibition of recruitment of osteoblast cells. Also, Lo and Fan (2005) confirmed that DMPA may cause bone loss in long-term users and such loss may be partially reversible after cessation of use. Transaminases were considered to be a more sensitive measure in evaluating liver function and damage (Howanitz and Howanitz, 1984). The elevation of aspartate and alanine aminotransferase in the present work are in accordance with Fakhry *et al.* (1988) and Taheri *et al.* (2006) who attributed this increase to hepatocellular damage induced by estrogen and progesterone. Further, Mukherjea *et al.* (1981) and Virutamasen *et al.* (1986) were reported alterations in carbohydrate metabolism and liver function in long-term users of DMPA. Ikekpeazu *et al.* (2009) reported liver malfunction after short-term use of hormonal contraceptive. Faddah *et al.* (2005) stated that liver functions (AST, ALP and Total Bilirubin) were showed activity and significantly elevated in the first year of DMPA administration. The present study reported that DMPA doses induced various alterations serum protein fractions as compared with the control groups. These alterations were manifested in polyacrylamide gel electrophoresis by defeciencey in the concentration of gamma globulin which in agreement with the results of Cunningham-Rundles *et al.* (1993) and Keren (1994) who reported that the deficiency of gamma globulin associated with allergy, metastatic carcinoma, autoimmune conditions and from defective in the synthesis of this protein. Also, reduction in Beta-globulins level in all treated groups in the present study was recorded and this confirmed by studies of Whicher (1980), Hamill *et al.* (1991) and Grant *et al.* (2009) Who reported reduction of total serum IgG following injection of female mice with DMPA 10 mg for 6 weeks. The obtained data of the present study showed reduced levels of beta globulins and this was in accordance with the report of Keren (1994) whereas, beta-globulins level reduced during use of contraceptives. Significant decrease in serum albumin level was reported in this study and confirmed by the study of Settlage *et al.* (1970) who reported induced significant decrease in albumin in five women were received DMPA 10 mg for 20 days of each cycle for three months. It also, confirmed by the study of Savitr *et al.* (2006) who reported hypoalbuminemia in subjects treated with progestins and they attributed the hypoalbuminemia to the direct effect of progestins on the metabolism of proteins and hypoalbuminemia in the present study may also attributed to hepatic dysfunction (Giboney, 2005; Heidelbaugh and Bruderly, 2006; Navarro and Senior, 2006 and Hoefs *et al.*, 2006) and this correlated with hepatocytes injury by DMPA and confirmed by the incidence of the histopathological lesions in liver tissues.

In the present study serum prealbumin level was increased with treatment of female rats with DMPA. This confirmed by Castaneda and Ruize (1994) who reported increase in the prealbumin level in severs hepatic and renal failure and tumors. A decrease in serum alpha-globulin levels was recorded in the sera of treated groups, this decrease confirmed by Settlage *et al.* (1970); Whicher (1980) and Fitzmaurice *et al.* (1989) who referred the elevation to acute inflammation. On the other hand, contraceptive agents, mostly sex steroids, influence the activity of many enzymes including ceruloplasmin (Kaushansky *et al.*, 1987). Ceruloplasmin or ferroxidase is a blue-coloured metaloprotein which migrates electrophoretically as an alpha-2-globulin (Hyde and Mellor, 1983). Normally ceruloplasmin accounts for 95% of total plasma copper and it acts as an oxidase agent and involves in the oxidation of ferrous to ferric ions (ferroxidase activity) to promote the binding of iron to apotransferrin (Planas and Friden, 1973 and Rosser *et al.*, 1972). Liver is the major site of ceruloplasmin synthesis and many factors including toxic agents and sex steroids have significant influence on this enzyme synthesis and metabolism. It has already been reported that contraceptive agents increase the enzyme concentration in the plasma (Liukko *et al.*, 1988). Also, deficiency of alpha-globulin indicates intravascular or extravascular hemolysis and associated with liver cirrhosis as reported by Jenkins and Fotherby (1980); Akpoviroro *et al.* (1981); Ritzmann & Daniels (1982) and Mackiewicz *et al.* (1992); Holladay *et al.* (1998) and Johnson *et al.* (2008).

Referring to histopathological lesions induced by DMPA doses in liver tissues these results were in a greement with Adieb *et al.* (1986) who reported similar observation in liver cells of female rat after sex hormones administration. Also, both Boseila *et al.* (1985) and Attia *et al.* (1994) reported dilatation of hepatic sinusoids, cellular infiltration and congestion of hepatic blood vessels following hormonal treatment. Many authors interpreted the vacuolation, fatty infiltration and necrosis induced by female sex hormones in liver tissues and this could be attributed to metabolizing of sex hormones in the hepatocytes which may leads to increase in the smooth endoplasmic reticulum and swollen mitochondria and cellular granularity as reported by (Nasonov, 1959), or partially attributed to the anabolic effect of estrogen and progesterone in forming mRNA that formed a new protein (Boseila *et al.*, 1985; Edress *et al.*, 1991; Attia *et al.*, 1994 and Ganong, 1995). However, Gray *et al.,* 1981 reported a direct effect of ovarian hormones on adipose tissue, role causing increased body weight and fat deposition. In the present study liver function studies showed sever alterations that indicate cellular injury in the liver. ALT is a more specific indication of liver disease, whereas AST

elevations may be secondary to damage of other organs (heart, kidney, brain, intestine, placenta). Alkaline phosphatase is associated with cellular membranes, and elevated levels may be caused by injury to the liver, bone, kidneys, intestines, placenta, or leukocytes. (Giboney, 2005; Heidelbaugh and Bruderly, 2006; Navarro and Senior, 2006; Hoefs *et al.*, 2006). Also, some liver function tests (LFTs) may be raised physiologically, for example in pregnancy and contraceptive use, or for reasons not associated with liver disease. However, suboptimal investigation of LFT abnormalities may lead to important treatable causes of liver disease (Pritchett, 2009). Finally, the findings of this study shed more light and traceable to effects of DMPA on the adult female rats and suggests a toxic potential of DMPA which makes this an important issue that is worthy of animal trials studying possible ill-effects. DMPA induced harmful alterations in the liver function test and histological details of liver. It demands the lowest possible use of effective doses of DMPA to minimize any potential risk. So, the use of hormonal contraceptives should be under the supervision of the physicians.

REFERENCES

Abe, M., T. Kumagi, S. Nakanishi, T. Yamagami, K. Michitaka, K. Abe, I. Okura, H. Yamashita, N. Horiike, and M. Onji, 2002. Drug-induced hepatitis with hepatic granuloma due to saridon. J. Gastroenterol., 37(12): 1068-72.

Adekunle, A.O., M.A. Okunlola, A.O. Arowojolu, O. Arinola and L.S. Salimonu, 2001. Serum immunoglobulins, total protein and albumin levels during UniplantR use by Nigerian women. Afr. J. Med. Med. Sci., 30(4): 265-8.

Adieb, N., S. El-Sharouni, K. Abdelzhaer and H. Labiba, 1986. Histopathological Study of the Liver, Pancrease, Kidney Suprarenal of Albino Rat under the Effect of Medroxy Progesterone Acetate". Egypt. J. Histol., 9(2): 349-356.

Adlercreutz, H. and R. Tenhunen, 1970. Some Aspects of the Interaction between Natural and Synthetic Female Sex Hormones and the Liver". Amer. J. Med., 49: 360-367.

Akpoviroro, J.O., M. Mangalam, N. Jenkins and K. Fotherby, 1981. Binding of the contraceptive steroids medroxyprogesterone acetate and ethynyloestradiol in blood of various species. Journal of Steroid Biochemistry, 14(5): 493-498.

Al-Rawi, M.M., 2002. Biochemical and Histological Studies on the Effect of Hormonal Replacement Therapy in the Old Female Rats (Rattus norvegicus) J. King Saud Univ., Science, 1: 59-69.

Attia, M.A., A.L.G. Ahmed, S.S. Ali and R. Sadia, 1994. "Effect of Combined Administration of Estrogen and Progesterone on the Histological and Histochemical Features of Liver and Spleen in Female Non-lactating rats". Assuit. Vet. Med. J., 31(62): 48-57.

Baily, N.T.J., 1994. Statistical methods in biology. 3rd edition. Cambridge University Press.

Bakry, S., 2005. Effect of Contraceptive Drug on the Development of mouse Embryos during Postimplantation Period. PhD Thesis, Faculty of Science, Al Azhar University, Nasr City, Cairo Egypt.

Boseila, A.W., A.M.F. Ragab, N.A. Saheh, M.I. Hassan and A. Bayomi, 1985. Histochemical Localization of Succinic Dehydrogenase Enzyme Activity in the Endometrium of Female Albino Rat under the Effect of Contraceptives". Egypt. J. Histol., 8: 215-221.

Castaneda, L. and P. Ruize, 1994. Duplicate prealbumin bands in urine. Association with hepatorenal failure. Am. J. Clin. Pathol., 101: 475-477.

Cauci, S., M. Di Santolo, J.F. Culhane, G. Stel, F. Gonano and S. Guaschino, 2008. Effects of third-generation oral contraceptives on high-sensitivity C-reactive protein and homocysteine in young women. Obstet Gynecol, 111(4): 857-64.

Cunningham-Rundles, C., Z. Zhou, S. Mankarious and S. Courter, 1993. Long-term use of IgA-depleted intravenous immunoglobulin in immunodeficient subjects with anti-IgA antibodies. J. Clin. Immunol., 13: 272-278.

Davenport, H.A., 1960. Histological and histochemical techniques. Saunders, W.B. Co., Philadelphia and London, 212-285.

Edress, N.M., S.R. El-Attar, M.F. Fahmy, M.O. Badr and M.M. Hanafi, 1991. "Clinopathologic and Histopathologic Studies on the Effect of Hormonal Contraceptive on the Liver, Kidney and Genital Organs of Female Albino rats". Zagazig Vet. J., 19(3): 768-748.

El-Allawy, R.M., M.M. Said, M.H. Ibrahim, M.S. Zohni and A.L. Attalla, 1984. "Certain Metabolic Changes as Influenced by Five Ovulatory Steroids". J. Drug Res., 15(1-2): 74-86.

El-Gendy, A.M. and A. Tohamy, 1998. "Hormonal Replacement Therapy in Female Rats. Hematological and Physiological Studies". Al-Azhar Bull. Sci., 9(2): 581-591.

Faddah, L.M., M.A. Al-Rehany, N.M. Abdel-Hamid and A.A. Bakeet, 2005. Oxidative Stress, Lipid Profile and Liver Functions in Average Egyptian Long Term Depo Medroxy Progesterone Acetate (DMPA) Users. Molecules, 10: 1145-1152.

Fajumi, J.O., 1984. The effects of Depo-Provera on serum protein levels in Nigerian women. J Steroid Biochem., 20(2): 581-583.

Fakhry, F.M., A.H. El-Anwar, M.M. Ateia and A. Abu-Ela, 1988. The Effect of Estrogen and Progesterone on Hepatorenal Function, Electrolytes and Trace Elements in Ovarictomized Rats". Zagazig Vet. J. XVI (2B): 121-131.

Fitzmaurice, M., R. Valenzulea and E.I. Winkelman, 1989. Serum protein electrophoresis pattern associated with decreased serum haptoglobin as a poor prognostic medicator in sever liver disease. Am. J. Clin. Pathol. 91: 365.

Folmar, L.C., S. Bonomelli, T. Moody and T. Gibson, 1993. The Effect of Short Time Exposure to there Chemicals on the Blood Chemistry of the Pinifish". Arch. Environ. Contam. Toxicol., 24: 83-86.

Ganong, W.F., 1995: *Review of Medical Physiology*. 17th Ed. Appleton & Hange Norwalk.

Ghonim, M.H., 1987. Some Toxocological Studies on Some Oestrogenic Compounds on Poultry and Laboratory Animals". *Ph.D. Thesis*, Zagazig University.

Giboney, P.T., 2005. Mildly elevated liver transaminase levels in the asymptomatic patient. Am Fam Physician., 71 :1105-10.

Giordano, N., P. Nardi, C. Santacroce, S. Geraci and C. Gennari, 2001. Acute hepatitis induced by cyproterone acetate. Ann Pharmacother, 35(9): 1053-5.

Grant, C., M. David, K. Zhang, L. Kelly E. Charles, A.Edward and B. Keith, 2009. Decrease in Glomerulonephritis and Th1-Associated Autoantibody Production After Progesterone Treatment in NZB/NZW Mice. Arthritis and rheumatism, 60(6): 1775-1784.

Gray, J.M., S.D. Dudley and G.R. Wade, 1981. *In Vivo* Cell Nuclear Biding of 17 B-(H3). Estradiol in Rats Adipose tissues". *Am. J. Physiol.,* 240 (Endorinol. Metab. 3): E43-E46.

Haffner, S.M., M.S. Katz, M.P. Stern and J.F. Dunn, 1989. Association of decreased sex hormone binding globulin and cardiovascular risk factors. Arteriosclerosis, 9: 136-43.

Hames, B.D. and D. Rick -Wood, (Eds.), 1981. Gel electrophoresis of proteins. Oxford University Press New York.

Hamill, R.L., J.C. Wood and B.A. Cook, 1991. Congenital a transferrinemia. A case report and review of the literature. Clin. Chem., 96: 215-218.

Hammond, G.L. Potential functions of plasma steroid-binding proteins. 1995. Trends Endocrinol Metab., 6: 298-304.

Heidelbaugh, J.J. and M. Bruderly, 2006. Cirrhosis and chronic liver failure: Part 1. Diagnosis and evaluation. AmFam Physician., 74: 756-62.

Hoefs, J.C., P.T. Chen, P. Lizotte, 2006. Noninvasive evaluation of liver disease severity. Clin Liver Dis., 10: 535-62.

Holladay, J.W., M.J. Dewey and S.D. Yoo, 1998. Pharmacokinetics and antidepressant activity of Fluoxetine HCl in transgenic mice with elevated serum alpha-1 acid glycoprotein levels. Drug Metab. Dispos., 26(1): 20-24.

Howanitz, P.J. and J.H. Howanitz, 1984. *In Clinical Diagnosis Management by Laboratory Methods*". 17th ed., T.B. Henry ed., W.B. Saunders, Philadelphia.

Humason, G.L., 1979. Animal tissue technique Library of congress (4th Ed.): 123-127.

Hyde, T.A. and L.D. Mellor, 1983. In Lynch's medical laboratory technology. Fourth edition. WB Saunders Comp. Philadelphia, London, 267.

Ikekpeazu, E.J., E.E. Neboh, I.C. Maduka, P.U. Nnadede and E. Ejezi, 2009. Effect of Duration of use of Hoemonal Contraceptives on Liver Function. Research Journal of Medical Sciences, 3(2): 52-55.

Jenkins, N. and K. Fotherby, 1980. Binding of the contraceptive steroids norgestrel and norethisterone in human plasma. Journal of Steroid Biochemistry, 13(5): 521-52.

Johnson, J.V., J. Lowell, G.J. Badger, J. Rosing, S. Tchaikovski, M. Cushman, 2008. Effects of oral and transdermal hormonal contraception on vascular risk markers: a randomized controlled trial. Obstet Gynecol., 111(2 Pt 1): 278-84.

Kahn H.S., K.M. Curtis and P.A. Marchanks, 2003. Effects of injectable or implantable progestin only contraceptives on insulin-glucose metabolism and diabetes risk. Diabetes Care, 26: 216-225.

Kaushansky, A., M. Frydman, H. Kaufman and R. Hamburg, 1987. Endocrine studies of the ovulatory disturbances in Wilson's disease (hepatolenticular degeneration). Fertil. Steril., 47(2): 270-273.

Keren, D.F., 1994. High-resolution electrophoresis and immunofixation: Techniques and interpretation. In: Proteins in serum identified by high resolution electrophoresis. 2nd Ed. by Butter worth-heinmann U.S.A., 41-96.

Lali, P., L. Chandra and R.P. Gupta, 1996. Serum immunoglobulin levels during contraceptive use of depot-Medroxyprogesterone acetate in Indian women: a preliminary study. Contraception, 53 (6): 363-5.

Liukko, P., R. Erkkola, E.W. Bergink, 1988. Progestagen-dependent effect on some plasma proteins during oral contraception. Gynecol Obstet Invest., 25(2):118-22.

Lo, S. and S. Fan, 2005. Bone loss associated with long-term use of depot Medroxyprogesterone acetate. Hong Kong Med. J., 11(6): 491-495.

Mackiewicz, A., H. Schooltink, P.C. Heinrich and S. Rose-John, 1992. Complex of soluble human Ih-6-receptor/IL-6 up regulates expression of acute-phase protein. J. Immunol., 149: 2021-2027.

Marshall, T., 2001. Sodium Dodecyl Sulfate Polyacrylamide Gel Electrophoresis of Serum after Protein Denaturation in the Presence or Absence of 2-Mercaptoethanol. CLINICAL CHEMISTRY, 30(3): 475-479

Meendering, J.R., B.N. Torgrimson, N.P. Miller, P.F. Kaplan, C.T. Minson 2008. Estrogen, medroxyprogesterone acetate, endothelial function, and biomarkers of cardiovascular risk in young women. Am. J. Physiol. Heart Circ. Physiol., 294(4): H1630-7.

Mingrone, G., A.V. Greco, A. Giancaterini, A. Scarfone, M. Castagneto, M. Pugeat, 2002. Sex hormone-binding globulin levels and cardiovascular risk factors in morbidly obese subjects before and after weight reduction induced by diet or malabsorptive surgery. Atherosclerosis, 161: 455-462.

Mukherjea, M., P. Mukherjee, R. Biswas, A.S. Chakraborty, J. Kushari, 1981. Effect of medroxyprogesterone acetate contraception on human serum enzymes. Int. J. Fertil., 26: 35-39.

Nakao, A., K. Sakagami, Y. Nakata, K. Komazawa, T. Amimoto, K. Nakashima, H. Isozaki, N. Takakura, and N. Tanaka, 2000. Multiple hepatic adenomas caused by long-term administration of androgenic steroids for a plastic anemia in association with familial adenomatous polyposis. J Gastroenterology, 35(7): 557-62.

Nasonov, D.N., 1959. *Reaction of Protoplasm and Spreading Stimulation*". 1st ed. Mosco. Leningrad.
Navarro, V.J. and Senior, J.R. 2006: Drug-related hepatotoxicity. N. Engl. J Med., 254: 731-39.

Paget, G.E. and J.M. Barnes, 1964. Interspecies dosage conversion schem in evaluation of results and quantitative application in different species. In: "Evaluation of drug activities: Pharmacometrics" Vol. 1, laurence, D.R. and Bacharach, A.L. [Eds.]; Academic press, London and New York, 160-162.

Planas, J. and E. Frieden, 1973. Serum iron and ferroxidase activity in normal, copper-deficient, and estrogenized roosters. Am. J. Physiol., 225(2): 423-8

Pritchett, S., 2009. Abnormal LFTs. Innovait., 2(3):140-147.

Przyjalkowski, Z. and A. Starzenska, 1985. Preliminary studies on the serum proteins of germfree and conventional mice infected with Trichinella Pseudosipralis only or stimultaneously with T. Spiralis Acta: Parasitologica Polonica. XXX(8): 63-71.

Pugeat, M., P. Moulin and P. Cousin, 1995. Interrelations between sex hormone-binding globulin (SHBG), plasma lipoproteins and cardiovascular risk. J. Steroid Biochem. Mol. Biol., 53: 567-72.

Raufman, J.P., D.L. Miller and J.J. Gumico, 1980. "Estrogen Induced Zonal Changes in the Liver Sinusoides". *Gastroent.,* 79: 1174-1182.

Ritzmann, S.E. and J.C. Daniele, 1982 Serum electrophoresis and total serum proteins. In: Ritzmann S.E. and Daniels, J.C. (Eds). Serum protein abnormalities: diagnostic and clinical aspects, 2, New York: Liss, 3-26.

Roschlau, G., 1977. Multiple nodular hyperplasia of liver associated with oral contraceptives. Zentralbl. Allg. Pathol., 121(6): 517-21.

Rosner, W., 1990. The functions of corticosteroid-binding globulin and sex hormone-binding globulin: recent advances: Endocr. Rev., 11: 80-91.

Rosser, C.R., L.E. Limbird, G.S. Wagner, S.T. Nerenberg, 1972. Combined isoenzyme analysis in the diagnosis of myocardial injury: application of electrophoretic methods for the detection and quantitation of the creatine phosphokinase MB isoenzyme. J. Lab Clin. Med., 80(4): 577-90.

Rumi, A., C. Somaglino, V. Ronchi and G. Pasqualin, 2000. A new case of hepatic adenomatosis. A critical review of the literature. G. Chir., 21(1-2): 37-43.

Savitr, R., E. Sponzilli and C. Wingerd, 2006. Effects of Steroid Contraceptives on Serum Protein Fractions. Brazilian J. Obstetrics & Gynecology, 48: 211-215.

Settlage, F., M. Nakamura, V. Davajan, K. Kharma and R. Mishell, 1970. A quantitative analysis of serum proteins during treatment with oral contraceptive steroids. Contraception, 1(2): 101-114

Taheri, M., M. Rahimi, M. Naderi, S. Ghavami, M. Mokhtari, H. Rashidi, M. Hashemi, 2006. Effects of a subdermal levonorgestrel contraceptive implant (Norplant) on serum cholesterol, triglycerides, ALT and AST in Iranian women. Contraception, 73(1): 56-8.

Tajada, M., J. Nerin, M.M. Ruiz, M. Sanchez-Dehesa and E. Fabre, 2001. Liver adenoma and focal nodular hyperplasia associated with oral contraceptives. Eur J Contracept Reprod Health Care, 6(4): 227-30.

United Nations Development Programme/United Nations Population Fund/WorldHealth Organization/World Bank, Special Programme of Research, Development and Research Training in Human Reproduction, 1997. Comparative study of the effects of two once-a-month injectable steroidal contraceptives (Mesigyna and Cyclofem) on lipid and lipoprotein metabolism. Contraception, 56: 193-207.

Virutamasen, P., C. Wongsrichanalai, P. Tangkeo, Y. Nitichai, D. Rienprayoon, 1986. Metabolic effects of depot-medroxyprogesterone acetate in long-term users: a cross-sectional study. Int. J. Gynaecol. Obstet., 24(4): 291-6.

Voetberg, G.A., J.C. Netelenbos, P. Kenemans, I.E. Peters-Muller and PH.M. Van De Weijer, 1994. "Estrogen Replacement Therapy Continuously Combined with Four Different Dosages of Dehydroprogesterone: Effect on Calcium and Lipid Metabolism". J. Clin. Endocrinol. Metab., 79: 1465-1469.

Westhoff, C., J.K. Jainb, I. Milsomc and A. Rayd, 2007. Changes in weight with depot medroxyprogesterone acetate subcutaneous injection 104 mg/0.65 mL. Contraception, 75: 261-267.

Whicher, J.T., 1980. The interpretation of electrophoresis. Br. J. Hosp. Med. 348-360.

Wilhelm, K., Barbara, S. and Rolf, W. 2003: Influence of changes in the concentration of sex hormone-binding globulin in human serum on the protein binding of the contraceptive steroids DMPA, levonorgestrel, and gestodene. The Journal of Steroid Biochemistry and Molecular Biology, 48(5-6): 573-580.

Xiang, A.H., M. Kawakubo, T.A. Buchanan and S.L. Kjos, 2007. A longitudinal study of lipids and blood pressure in relation to method of contraception in Latino women with prior gestational diabetes mellitus. Diabetes Care, 30(8): 1952-8.

Zilva, J.F., P.R. Pannall and P.D. Mayne, 1988. *Clinical Chemistry in Diagnosis and Treatment*" 5th ed. Singapore: Edward Arnold PG, Asian Edition.