




ISSN:1991-8178

Australian Journal of Basic and Applied Sciences

Journal home page: www.ajbasweb.com



Identification of Tooth Decay in Panoramic X-ray using Image Processing

¹Sabarinathan. K.M, ²Mahalakshmi.B, ¹Shoba. S, ¹Vidhya. P.G., ¹Siva. K, ¹Dhanesh Kumar. G, ³Natarajan Vijayarangan.

¹Final year students, B.E-Computer Science and Engineering, K.S.Rangasamy College of Technology, Tiruchengode,India.

²Associate Professor, K.S.Rangasamy College of Technology, Tiruchengode, India.

³Senior Scientist, TCS Innovation labs, CTO Organization, TCS Ltd, India

ARTICLE INFO

Article history:

Received 12 November 2014

Received in revised form 26 December 2014

Accepted 29 January 2015

Available online 10 February 2015

Keywords:

Histogram equalization, Panoramic radiography, Run Length Encoding; Wiener filter.

ABSTRACT

A panoramic x-ray or radiograph shows the entire teeth structure along with jaws. It is an ideal diagnostic aid which poses less radiation exposure. About 60% of dental units are using panoramic x-ray. But panoramic x-ray lacks of image quality since the image does not provide a precise and detailed structure of single tooth and it can only provide an overall idea of affected teeth. In order to use the panoramic x-ray for automated tooth decay detection, the quality of the x-ray image must be improved and is done by using various image processing techniques. Finally, a diagnosis report is generated by our automated dental diagnosis system for the patient.

© 2015 AENSI Publisher All rights reserved.

To Cite This Article: Sabarinathan. K.M, Mahalakshmi.B, Shoba. S, Vidhya. P.G., Siva. K, Dhanesh Kumar. G, Natarajan Vijayarangan., Identification of Tooth Decay in Panoramic X-ray using Image Processing. *Aust. J. Basic & Appl. Sci.*, 9(6): 60-64, 2015

INTRODUCTION

1.1 Image processing:

Digital Image processing is defined as the processing of an image to generate the output in the form of image or parameters of the image or characteristics of image. Pictorial information has to be improved for human interpretation or usage of image data for various purposes such as storage, transmission and representation of the machine perception.

1.2 Dentistry:

Dental Caries: Dental caries is one of the most common diseases found all over the world. Dental caries has affected all age groups in modern times. Dental caries occurs due to infectious microbiological agents which results in localized dissolution in the teeth and destruction of the calcified portions of the teeth. The proposal deals with the identification of tooth decay extent using panoramic x-ray (Anita Patel, *et al.*, 2012).

1.3 Panoramic x-ray:

Panoramic radiography is the one and only radiographic technique that provide the view of the entire teeth structure and jaws portion, from condyle to condyle, on one film. Panoramic x-ray with entire tooth structure is shown in fig 1. It is commonly taken on the initial visit to the dental office and is the mainly used x ray in the aid of diagnostic decisions.

Advantages:

Panoramic radiography is considered as essential in radiographic diagnosis. The use of panoramic radiography in private practice is currently on the rise. The benefits of using panoramic x-ray are simplicity, time & rapidity of the procedure, client cooperation, less radiation exposure, minimal infection control, cost effective.

Disadvantages:

Though panoramic x-ray has many advantages, the identification of tooth decay extent is very difficult in panoramic x-ray. Since very less intensity of radiation is used, the resolution of the resultant x-ray is very less, i.e., poor quality x-ray image. This poor quality poses difficulty in identification of tooth decay extent.

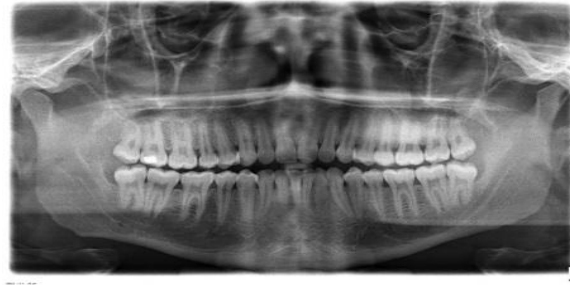


Fig. 1: Digital Panoramic x-ray

2. Existing System:

Panoramic x-rays are very poor in quality. There are many techniques proposed to improve the quality of x-rays. The existing enhancement techniques considered various problems in the x-rays and suggested different approaches to enhance various parameters of the x-ray image. Noise in the image could be removed by various noise removal techniques. Contrast of the images is enhanced by various techniques. The existing segmentation methods are based on normal edge detection techniques like Sobel method, Canny method and entropy method (Thresholding) (Raman Maini and Himanshu Aggarwal, 2010).

Sobel: It is used to identify the horizontally and vertically edges in the image (Manoj Vairalkar, K., S.U. Nimbhor, 2012). The mathematical expression for it is:

$$G = \sqrt{G_x^2 + G_y^2} \quad (1)$$

Canny: It uses four filters to identify the horizontal, vertical and diagonal edges in the image. The mathematical expression for it is:

$$G(x,y) = \frac{1}{2\pi\sigma^2} e^{-\frac{x^2+y^2}{2\sigma^2}} \quad (2)$$

Once the edges are detected then the particular single tooth can be extracted from the entire image.

Thresholding: Another method for extracting the single tooth is thresholding. In this technique the threshold value of the image (usually mean value is taken as threshold value) is used to extract the tooth from other background details.

2.1 Drawbacks:

Thresholding based method can be used for segmentation of the teeth but they usually fail to classify between the teeth and bone areas as their intensities are more or less similar in a case of uneven exposure. (Anita Patel, *et al.*, 2012) Automation is not possible if the techniques produce inaccurate results. The normal x-ray image could not

show the decay extent below 30%. Hence there must be an automated system which could diagnose the extent accurately. This will be very useful for the treatment purpose.

3. Proposed System:

3.1 Proposed Technique:

Segmentation Using Pixel Wise Adaptive Mean Thresholding: In the data set collected, it is found that the exposure is uneven in the entire image. Normal thresholding technique is not suitable for such images, because the thresholding value should vary according to the exposure. Hence a new technique called Adaptive Mean Thresholding is followed. In this technique, mean is calculated for every column in the image, so that the threshold value of the particular column can be fixed to match the uneven exposure.

The following steps are followed for segmentation:

Step1: Calculate the mean value for every column of pixel.

Step2: The mean values of the columns are modified according to the exposure noted from the dataset and used as adaptive threshold values for each column.

Step3: The pixel values below those adaptive threshold values for each column are considered as the background.

Step4: With this classification, background details are separated from the foreground tooth area.

3.2 Module Description:

3.2.1 Preprocessing:

This phase involves two processes: 1. Cropping, 2. Enhancement.

1. Cropping: This is the initial process in which the necessary region of the entire image is cropped. In general panoramic x-ray has the entire nasal part and jaws from ear to ear from which only the tooth structure must be extracted.

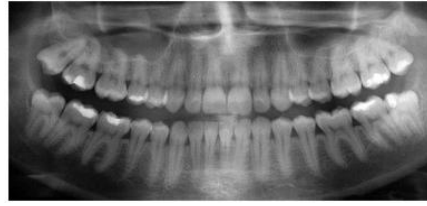

Fig. 3: Cropped x-ray image

2. Enhancement: Enhancement of a dental radiograph is the process of producing an improved quality image out of an input image of a dental radiograph (EyadHaj Said, *et al.*, 2010). In pre-processing two phases are involved: i. Noise Removal

ii. Histogram Equalization.

i. Noise Removal: Aquisited panoramic x-ray images usually suffers from Gaussian noise. Many techniques are available for denoising, but one of the efficient way of de noising is the wiener filtering method. The following steps are involved in the filtering:

Step 1: Generating a square mask and a disc mask

Step 2: Perform a blurring step of the image with the following filter

Step 3: Add a Gaussian (white) noise is show in Fig 4.

Step 4: Perform a restoration of this built image by using the simplified Wiener restoration filtering is shown if Fig 5.

ii. Histogram Equalization: Histogram equalization is the distribution of intensity of pixels throughout the image to achieve the higher and required contrast. Histogram equalization is used for contrast adjustment is show in fig 6.

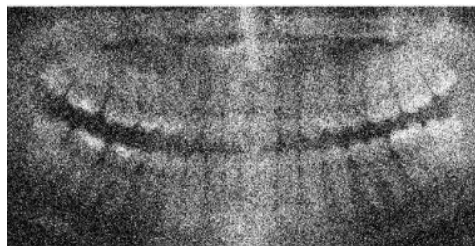


Fig. 4: X-ray image added with Gaussian Noise

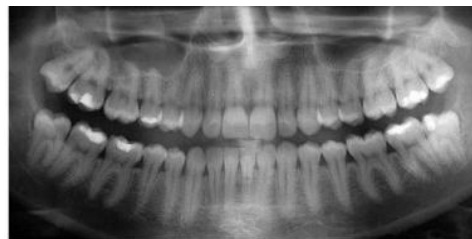

Fig. 5: Restored x-ray image

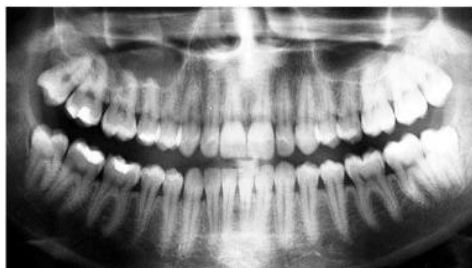

Fig. 6: Contrast enhanced x-ray image

3.2.2 Image Segmentation:

Image segmentation is the process of retrieving particular objects from the entire image. The single

tooth must be extracted form the entire teeth structure to process separately. This can be done in many ways. One of the way is to detect the edges of

the tooth and extract the single tooth from the image. Many edge detecting algorithms are deployed for this purpose such as detection based on gradient, color, shapes etc. But whatever be the edge detection technique used, it'll not be suitable for this type of x-ray images. Because the tooth may overlap with each other. So the edges cannot be detected with greater accuracy and to crop them morphologically poses very great difficulty. Hence an alternate approach is

proposed which involves two successive processes (EyadHaj Said, *et al.*, 2010; Xin Li, *et al.*, 2011). First the two level separations of the upper and lower jaws through horizontal segmentation is show in fig 7. The separated jaws are given as input one by one and then vertical segmentation is done. Then vertical segmentation to separate individual tooth from the respective jaws is show in fig 9. The final output of the segmented tooth is show in fig10.

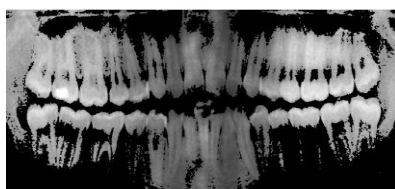


Fig. 7: Jaws Segmentation.

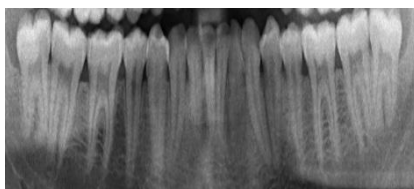


Fig. 8: Lower jaw

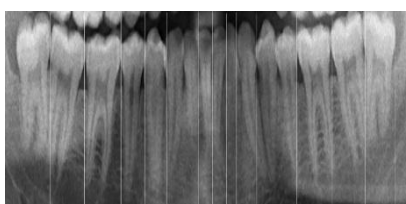


Fig. 9: Teeth Segmentation

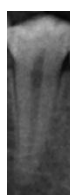

Fig. 10: Segmented Tooth

3.2.3 Classification:

The segmented tooth is analysed for its color feature and then depending upon the amount of black pixels, the decay extent is identified. The Run Length Encoding technique is used for this purpose. The gray image is converted into black and white image by thresholding method. The consecutive black and white pixels are counted and ordered to find the black spots inside the tooth region. In this technique, each row is scanned for the black pixels that are found after the first white pixel. Only such black pixels are counted so that the decay alone can be measured discarding the background region. Once

the extent is identified, based on the survey from doctors, the treatment method and standard cost of the treatment are estimated for all teeth (Robert M Haralick, *et al.*, 2000). The complete report is generated which contains all these details for each and every tooth.

Conclusion:

Thus our system could automate the diagnosis of tooth decay and generate a report. A panoramic X-ray is a good way for screening many types of problems but is not good for detecting tooth decay. But our system could overcome this issue using

various image processing techniques and detect the decay extent using panoramic x-ray. The automated system generates the report which comprises the following details: Decay extent of every tooth, treatment method for every tooth, and cost of the treatment.

REFERENCES

- Anita Patel, Pritesh Patel, and Ashtha Baxi, 2012. "Analysis of Dental Image Processing For Human Identification", *International Journal of Engineering Research and Technology*, 1(10): 177-204.
- Oke Alice O., O. Omidiora Elijah, A. Fakolujo Olaosebikan, S. Falohun Adeleye and S.O. Olabiyisi, 2012. "Effect of Modified Wiener Algorithm on Noise Models", *International Journal of Engineering and Technology*, 2(8): 1024-1033.
- Ce Liu, Richard Szeliski, C. Lawrence Zitnick and William T Freeman, 2008. "Automatic Estimation and Removal of Noise from a Single Image", *IEEE Transactions on Pattern Analysis and Machine Intelligence*, 30(2): 299-313.
- Vijaykumar, V.R., P.T. Vanathi and P. Kanagasabapathy, 2011. "Fast and Efficient Algorithm to Remove Gaussian Noise in Digital Images", *IAENG International Journal of Computer Science*, 1(11): 14-23.
- Vertika Agarwal, 2011 "Analysis of Histogram Equalization in Image Preprocessing", *BIOINFO Journal Human-Computer Interaction*, 1(11): 4-7.
- Manoj Vairalkar, K., S.U. Nimbhor, 2012. "Edge Detection of Images Using Sobel Operator" *International Journal of Emerging Technology and Advanced Engineering*, 2(1): 177-183.
- Raman Maini and Himanshu Aggarwal, 2010. "Study and Comparison of Various Image Edge Detection Techniques", *International Journal of Image Processing*, 3(1): 1-12.
- EyadHaj Said, GamalFahmy, DiaaNassar, and HanyAmmar, 2010. "Dental X-ray Image Segmentation", *International Journal on Computer Science and Electrical Engineering*, 5(4): 175-193.
- Xin Li, Ayman Abaza, Diaa Eldin Nassar, and Hany Ammar, 2011. "Fast And Accurate Segmentation of Dental X-Ray Records", *Journal of Engineering and Technology*, 2(8): 688-697.
- Robert M Haralick, K.Shanmugam and Hak Dinstein, 2000. "Texture Features for image Classification", *International Journal of Scientific & Engineering Research*, 3(7): 610-621.